M2 MICROBIOLOGY SUMMARY

BACTERIA

1.1 | Identification of Bacteria 1
1.2 | Bacteria list 4

FUNGI

2 | Fungi 24

VIRUSES

3.1 | Virus list 31
3.2 | Hepatitis 41
3.3 | HIV 45

PARASITES

4.1 | Malaria 46

Note – this set of notes does not include

- TB: see microbiology & pathology notes
- Other parasites: look up at least toxoplasma

NIGEL FONG 2012/2013

Identification of Bacteria.

M2 Microbiology
Nigel Fong 2012

The most basic way of classifiying bacteria involves the gram stain. Gram positive bacteria appear blue and gram-negative bacteria appear red. However some bacteria are not stainable.

Aerobic Gram Positive Bacteria.

Gram positive cocci in chains or doublets are ***Streptococci***. Gram positive cocci in clusters are ***Staphylococci***. If in doubt, test for catalase. *Streptococci* are catalase negative, and *Staphylococci* are catalase positive.

Streptococci are subdivided according to hemolysis of blood agar, as well as Lancefield grouping. Beta-hemolytic streps result in an area of clearing (hemolysis). If Lancefield Group A, ***S. pyogenes***. If Lancefield Group B, ***S. agalactiae***. Alpha-hemolytic streps turn blood agar green; they are not actually hemolytic. Of the alpha-hemolytic streps, ***S. pneumoniae*** is optochin sensitive while the optochin resistant ones are the '**Viridans Streptococci**'. ***Enterococci*** and *S. bovis* can be alpha, beta, or non (gamma-) hemolytic but are all Lancefield Group D. Other *Streptococci* include the *Arginosus* and *Abiotrophia* groups.

Staphylococci are subdivided according to the coagulase test. ***S. aureus*** is coagulase positive. The 'coagulase negative staphylococci' include *S. epidermidis*, *S. saphrophyticus*, and *S. lugdumensis*.

There are a number of aerobic gram positive bacilli. The corynebacteria family includes ***Corynebacterium diptheriae***, *C. ulcerans*, *C. jeikeium*, and *C. minutissimum*. *C. diptheriae* grows on selective Tinsdale medium to form 'chinese letters', and causes a precipitin line on an Elek plate. The bacillus family of sporing large gram positive rods include ***Bacillus anthracis*** and *B. cerus*. The ***Listeria*** family of small gram positive rods include *L. monocytogenes*. ***Nocardia*** spp. form branching beaded filaments. Other gram positive rods include ***Lactobacillus*** spp, *Erysipelothrix rhusopathiae*, *Arcanobacterium haemolyticum*, and *Rhodococcus equi*.

Aerobic Gram Negative Bacteria.

Gram negative diplococci are ***Neisseria*** or ***Moraxella***. Gram negative rods include **Enterobacteriaceae**, ***Pseudomonad***, and ***Vibros*** families. Of these, only *Enterobacteriaceae* are oxidase negative; the others are oxidase positive. Growth media can also be used to identify bacteria: *Enterobacteriaceae* grow on MacConkey agar, which contains bile salts, while *Vibros* grows on TCBS (thiosulphate – citrate – bile salt – sucrose) media.

Neisseria meningitidis and ***Neisseria gonorrhoeae*** are delicate organisms, requiring charcoal transport medium and chocolate agar to grow. ***Moraxella catarrhalis*** is a related species.

The Enterobacteriaceae can be subdivided according to their ability to ferment lactose. Lactose fermenters appear pink or red on MacConkey agar, while non-lactose fermenters appear yellow. The lactose fermenters are ***Escherichia coli*** and *Klebsiella* spp. The non lactose fermenters are: ***Salmonella*** (**Typhi, Paratyphi A / B / C**, Typhimurium or Enteritidis), ***Shigella dysentriae***, *Shigella sonnei*, *Shigella boydii*, *Shigella flexneri*, and *Proteus* spp.

The Pseudomonads are non-fermentive. Very characteristically, ***Pseudomonad aeruginosa*** produces a green diffusible pigment, and ***Burkholderia pseudomallei*** grows in wrinkled colonies. Other pseudomonads include *Burkholderia cepacia* and *Stenotrophomonas maltophilia*.

The Vibros are short and curved rods. ***Vibros cholerae*** is fermentive and appears as yellow colonies on TCBS media. Non-fermentive Vibros species appear green, these include *Vibros parahemolyticus* and *Vibros vulnificus*.

There are a number of fastidious (difficult to grow) gram negative rods. The bacteria that follow fall into this class –

Haemophilus spp. grows poorly on blood agar and prefers chocolate agar. ***Haemophilus influenzae*** requires X and V factors while *Haemophilus ducreyi* requires X factor only, and appears as a 'shoal of fish'. *H. influenzae* is further subdivided into encapsulated strains a-f, and non-encapsulated strains.

Haemophilus influenza is part of the **HACEK** group. Other members are: ***Actinobacillus actinomycetemcomitans*** (now reclassified as *Aggregatibacter*), ***Cardiobacterium hominis***, ***Eikenella corrodens***, and ***Kingella kingae***.

Klebsiella (Calymmatobacterium) granulomatis shows up as Donovan bodies in macrophages, while ***Yersinia pestis*** has a classical 'safety pin' appearance. There are more members of Yersinia: *Y. enterocolitica* and *Y. pseudotuberculosis*.

Other fastidious gram negative rods include: ***Bordetella pertussis*** & *Bordetella parapetussis*, *Brucella spp*, ***Legionella pneumophilia***, *Bartonella baciliformis / quintana / henselae / clarridgeiae*, *Pasteurella multocida*, *Francisella tularensis*, and *Actinobacter baumanii*.

Anaerobic bacteria.

The anaerobes are killed by oxygen. Of the anaerobes, only ***Clostridium*** forms spores. The *Clostridia* are gram positive rods. ***C. perfringens*** produces an area of opacity on Nagler plates (but not on the side with antitoxin). ***C. tetani*** appears like drumsticks due to large terminal spores. The other important *Clostridia* are ***C. botulinum*** and ***C. difficile***.

Non-sporing anaerobes often give mixed infections. *Actinomycosis israelli* forms gram positive branching filaments (like Nocardia). Other non-sporing anaerobes include *Fusobacterium necrophorum*, and *Bacteriodes fragilis.*

Spiral bacteria.

The spiral bacteria have a characteristic spiral shape. Note that the term 'spirochete' refers only to ***Treptonema*** spp, ***Borrelia*** spp, and ***Leptospira*** spp.

Camphylobacter and ***Helicobacter*** species are gram negative spiral bacteria that can be visualized with microscopy. They grow only in micro-aerophilic conditions (neither aerobic nor anaerobic) and are oxidase positive. The *Camphylobacter* include ***C. jejuni***, ***C. coli,*** *C. fetus*. The *Helicobacter* include ***H. pylori***, *H. cinaedi*, *H. fenneliae*. *H. pylori* is also urease positive.

Treptonema includes multiple species but ***T. pallidium*** is the main one. *T. pallidium* is too small to be seen on microscopy – dark ground illumination has to be used. ***Borellia recurrentis*** and ***B. duttoni*** can be seen on peripheral blood films, while ***B. burgdorferi*** cannot. Other spiral bacteria include ***Leptospira interrogans***, *Spirilium minus*, and *Streptobacillus moniliformis*.

Others.

Gram stains are not useful for some bacteria.. ***Mycoplasma*** spp. and ***Chlamydia*** spp. are small and have no/little peptidoglycan cell wall, so they cannot be stained. ***Rickettsia*** spp. and cousins are hard to culture, so serological diagnosis is usually made. ***Mycobacterium*** spp. simply refuses to take up gram stain. Of these, all except *Mycoplasma* spp. are obligate intracellular pathogens.

The *Mycoplasmas* include ***M. pneumoniae***, *M. hominis*, *M. genitalium* and others. *M hominis* has a characteristic 'fried egg colony' appearance, while *M. genitalium* looks like protruding genetalia under electron microscopy.

Chlamydia tracheomatis is divided into three groups of serovars: (1) serovars A, B, Ba, and C, (2) serovars L1, L2, L3, (3) serovars D-K. Each group causes a different disease pattern. Other Chlamydia bacteria includes *Chlamydophilia. psittiaci* and *Ch. pneumoniae*.

The *Rickettsia* family are technically small gram negative bacteria, however they are hard to culture and diagnosis is usually serological. These include ***R. typhi***, ***R. prowazeki***, ***R. rickettsii***, and ***Orientia tsutsugamushi***. For *Ehrlichia chaffeensis*, *E. ewingii*, *Anaplasma phagocytophilus*, and *Neorickettsia sennetsu*, morulas in the WBC they infect can sometimes been seen. ***Coxiella burnetti*** can form resistant spores.

Mycobacterium tuberculosis, M. leprae and environmental *Mycobacterium* are acid-fast and can be stained with Ziehl-Nielson or Auramine stains. They are slow growers, taking 6-8 wks to culture. Environmental Mycobacteria include *M. kansasii, M. malmoense, M. xenopi, M. avium*-intracellulare complex, *M. haemophilum, M. cookei, M. hibernae, M. marinum*, and *M. ulcerans*. *M. kansasii* and *M. marinum* are photochromogens, producing pigment in light only. Additionally, *M. fortuitum*, *M. abscessus*, and *M. chelonei* complex are rapidly growing (within 1 week).

STREPTOCOCCI & ENTEROCOCCI

Gram + cocci in chains / doublets, catalase –ve Facultative anaerobes

MICROSCOPY		BACTERIA	FROM	VIRULENCE / EPIDEM	CLINICAL PRESENTATION	APPROACH & TREATMENT
β-hemolysis	Lancefield A	***S. pyogenes***	Resp droplets Direct contact	• M prot prevents phagocytosis. • SPE (pyrogenic exotoxins) • Streptolysins O, S • Hyaluronidase	• Pharyngitis/tonsillitis, w otitis media etc, post influenza pneumonia • Scarlet fever (SPE A/C aka erythrogenic toxins), • Erysipelas, impetigo, cellulitis, necrotising fascitis • Bacteriemia, septicemia, toxic shock syndrome **Autoimmune complications** • Acute Rheumatic Fever: polyarthritis, carditis, valve damage predispose to endocarditis • Acute Glomerulonephritis (immune cplx dx)	Penicillin (always S) x10 days Erythromycin Clindamycin (severe infection) Surgery for necrotising fascitis **Revised Jones Criteria** (ddx ARF): *Need 2 maj OR 1 maj + 2 min + evidence of strep* **Major**: carditis, polyarthritis, chorea, erythema marginatum; s/c nodules **Minor:** fever, arthralgia, ↑ESR/CRP, ↑ PR intv **Evidence of strep:** ↑ ASO, throat culture, antigen
	Lancefield B	***S. agalactiae***	Vagina, colon		• Neonatal: septicaemia, pneumonia, meningitis • Post-partum infections • Opportunistic infection	As above + gentamycin Prophylaxis for at risk mothers
	Lancefield C/G				• Sore throat, soft tissue infection, sepsis, etc	
α-hemolysis	Optochin S Draughtsmen colony Diplococci	***S. pneumoniae***	Resp droplets Carry in throat	• Anti-phagocytic capsule • Pneumolysin: mem damage	• Pneumonia (usu lobar), empyema, abscess • Meningitis, bacteraemia, septicaemia (endocarditis rare) • URTI, otitis media, sinusitis * *esp immunocompromised, asplenia/hyposplenic, chronic lung/heart/liver/renal dx, DM, cancer, young/old*	Penicillin, Amoxicillin (Avoid penicillin in meningitis as decreased suscep common) **Vaccine:** Conjugate vaccine available
	Optochin R	***Viridans Strep***	Mouth flora Dental plaque		• Dental caries • Subacute bacterial endocarditis	
? hemolysis	Lancefield D Diplococci	***Enterococci***	GIT Nosocomial		• Nosocomial infection • UTI, bacteremia, endocarditis	Ampicillin, Vancomycin (+ Genta) Cephalosporin R, some amp R, VRE
		S. bovis	GIT		• Endocarditis • S bovis in blood assoc with bowel carcinoma	Penicillin
Misc		***Arginosus***	Mouth/gut flora		• Abscesses	Penicillin
	Nutritionally var	***Abiotrophia***	Oral flora		• Endocarditis	

STAPHYLOCOCCI

Gram + cocci in clusters, catalase +ve. Facultative anaerobes

Note: tube coagulase test detects free coagulase, slide coagulase test detects bound coagulase (bound to organism surface)

Typing of S aureus (based on susceptibility to phages) used in suspected outbreak.

MICROSCOPY	BACTERIA	FROM	VIRULENCE & EPIDEM	CLINICAL PRESENTATION	APPROACH & TREATMENT
Coagulase + golden yellow hemolysis	***S. aureus***	Carried in ant nares Endogenous inf Transmit by: contact airbourne, cross-inf	Cell wall assoc: adhesion, capsule, protein A inhibits opsonization Extracellular: panton-valentine leukocidin destroys phagocytes, others causing tissue damage	**Due to toxins** (only certain strains) • S aureus multiplies at room temp, tolerates high salt conc. Release heat-stable enterotoxins: rapid food poisoning, vomiting • Toxic shock syndrome toxin (TSST-1: superantigen cross-links MHC II to TCR non-specifically, activating many T cells to release cytokines): TSS, fever, diffuse rash, hypotension. Associated with tampon. • Epidermolytic toxins: staph scalded skin syndrome, Ritter's disease, pemphigus neonatorum, bullous impetigo **Pyogenic infections**: common & very rarely devastating • Skin: boil, folliculitis, carbuncle, impetigo, cellulitis, necrotising fascitis • Int: thrombophlebitis, osteomyelitis, septic arthritis, abscesses, waterhouse-friderichsen syn (bleeding into & failure of adrenals) • Rapidly progressive endocarditis, • Pneumonia (not common) • In IV drug abusers – RHS endocarditis, staph pneumonia • Line-related sepsis	**Treatment:** S aureus are usu R to penicillin (due to beta-lactamase) • Incision & drainage • Use cloxacillin, erythromycin • Do not use antibiotics in staph food poisoning, it can't remove enterotoxin **MRSA** • R to penicillin, penems, cephalosporin • Ex ceftaroline & ceftobiprole • Use Vancomycin, linezolid, daptomycin.
Coagulase -	***S epidermidis***	Skin		Line-related sepsis, device-associated infections via biofilm formation (prosthetic valves, CSF fluid shunts, peritoneal dialysis, lines)	Many strains multi-R but S to vancomycin. Remove foreign items/lines
	S saprophyticus	Skin		UTI esp in sexually active young women	
	S lugdunensis	Perineum		Aggressive: endocarditis, osteomyelitis	

NEISSERIA & MORAXELLA

Gram – diplococci (often inside neutrophils), oxidase +ve (turns purple)
Further identification is via sugar fermentation reactions, mass spectroscopy, or molecular techniques.

MICROSCOPY	FROM	VIRULENCE & EPIDEM	CLINICAL PRESENTATION	APPROACH & TREATMENT
N. meningitidis	Carried in nasopharynx Transmitted via respiratory droplets or close contact	Lipo-oligosaccharide Antiphagocytotic capsule (A, B, C, Y, W-135 subgroups) Immunity dpd on antibody. **Epidemeology:** Highest incidence in young children, lesser peak in adolescence	• Meningococcaemia, shock due to endotoxin in fulminant meningococcaemia, • Meningitis • Haemorrhagic rash (petechiae, purpura, ecchymosis), also in conjunctiva and mucus membranes. Non-blanching when compressed under a glass (tumbler test). • Waterhouse-Friderichsen Syn: hemorrhage into adrenals • Rare: skin necrosis, pneumonia, pericarditis, endocarditis, conjunctivitis, arthritis.	**Diagnosis:** culture blood, CSF, aspirate from rash, PCR on throat swab if already taken antibiotics **Treatment:** Benzylpenicillin, Ceftriaxone. • To clear throat carriage, ceftriaxone. • Must treat chronic meningococcaemia to avoid acute infection. **Prophylaxis:** give close contacts rifampicin, ciprofloxacin, ceftriaxone. **Vaccination** available but NOT for group B • Indications: splenectomy, travel to common infection (Hajj, meningitis belt), local outbreaks, USA adolescents & at risk groups • Conjugate vaccine provides long-term protection, even to infants (but not polysaccharide vaccine)
N. gonorrhoeae	STD If in children: - sexual abuse or - poor hygiene Carriage in female endocervical canal	Lipo-oligosaccharide Fimbriae & outer-membrane proteins w high antigenic variation. Re-infections occur, immunity does not develop.	**Males:** • acute urethritis, discharge, dysuria, proctitis • Gays: proctitis (rectal inflammation) **Females:** may be asymptomatic or show • Dysuria, vaginal discharge • Acute salpingitis, acute pelvic inflammatory disease, Fitz-Hugh-Curtis syn (inf around liver) • Prepubertal: vulvovaginitis Disseminated inf possible: fever, joint pain, small pustular skin lesions Babies may be inf by mothers in delivery: gonococc. conjunctivitis (ophthalmia neonatorum).	**Diagnosis**: • Males: sample urethra, throat, rectum. Gram stain urethral discharge is diagnostic • Females: sample urethra, endocervix (not vagina), rectal, throat. Normal flora complicates. Need selective media to suppress growth of unwanted species • Delicate. Use charcoal transport medium, or directly plate after collection. Grow on chocolate agar (slow on blood agar) • Use confirmatory test for gonococcus in case with legal implication **Treatment** • IM ceftriaxone + Oral azithromycin • Antibiotic or silver nitrate eyedrops for newborn babies **Vaccination** unavailable due to antigenic variation.
M. catarrhalis	Upp resp tract flora		Chest infections in those with pre-existing disease or immunocompromised.	Co-amoxiclav

ENTEROBACTERIACEAE (coliforms)

Gram – rods
Oxidase negative
Grows on MacConkey agar (with bile salts)

Facultative anaerobes

Identification:

- On MacConkey medium, lactose fermenters (LF) produce acid and turn pink/red. Non-lactose fermenters (NLF) appear colourless/yellow.
- Further identification requires biochemical reactions and/or antigen detection (cell wall O antigen, flagellum H antigen)

General presentation:

- GIT operations: release of enterobacteriaceae can cause wound infection, peritonitis, abscesses.
- Nosocomial inf: hospitalized pt often widely colonized (esp UTI, wound, lung inf); antibiotics displace normal flora and select for R coliforms. Can lead to septicaemia
- Causes meningitis: neonates, after head trauma / neurosurgery. (also possible in septicemic pt, older adults, immunosuppressed pt)

MICROSCOPY	BACTERIA	FROM	VIRULENCE	CLINICAL PRESENTATION	APPROACH & TREATMENT
NLF	***Salmonella*** **Typhi** **Paratyphi A/B/C**	Not normal flora. Fecal-oral spread from other humans	**Course:** • 1st invasion of ileal mucosa, multiply in mesenteric LN • 1st bloodstream inv: multiply in macrophages of many organs • 2nd bloodstream inv: clinical presentation of typhoid fever • 2nd intestinal inv: excretion of infected bile into gut	**Typhoid fever** • Incubation period 10-14d • Slowly-rising fever with relative bradycardia (10-14d then falls) • Cough, headache, abdominal pain, anorexia, epistaxis. • May have either constipation or diarrhea. • Splenomegaly & hepatomegaly, rose spots. • Relapse or chronic carriage possible **2nd intestinal invasion**: typhoid ulcers, severe hemorrhage, perforation (of Peyer's patches). Significant mortality.	**Diagnosis:** • Blood cultures positive early, stool/urine positive later. • Serological diagnosis (Widal test) less reliable. **Treatment:** Ceftriaxone, Ciprofloxacin Vaccination for travelers Public health, sanitation.
NLF	***Salmonella*** **Typhimurium** **Enteritidis,** **etc**	Not normal flora. Poorly-cooked food contaminated with animal feces.		• Self-limiting food poisoning : Diarrhoea, abdo pain, vomiting, sometimes fever • May have transient bacteremia & local inf of atheromatous plaques, prostheses, osteomyelitis (esp sickle cell pt), meningitis (esp neonates), UTI, mycotic aneurysm. • Invasive disseminated inf in HIV, SLE, and immunosuppressed pt	
LF	***Escherichia coli***	Gut flora	Some virulent strains: • Enteropathogenic (EPEC) • Enterotoxigenic (ETEC) • Enteroinvasive (EIEC) • Enterohemorrhagic (EHEC), also known as VTEC, STEC. • EHEC O157 caused many cases • Others e.g. EAggEC, DAEC. Low infective dose.	• UTI (commonest cause of community-acquired UTI) • Neonatal infections: septicaemia, meningitis (due to incomplete closure of meninges, as in spinal bifida) • Sepsis associated with gut, due to disease or post-operative • Hospital acquired infection **Virulent strains:** • EPEC/ETEC commonly diarrhoeal disease, traveller's diarrhea • EIEC causes Shigella-like dysentery. • VTEC toxin also cause hemorrhagic colitis (bloody diarrhea) and hemolytic-uraemic syndrome (HUS: acute renal failure, micro-angiopathic hemolytic anemia, thrombocytopaenia	**Diagnosis:** Only done if an outbreak is suspected • Selective agar for O157 • Toxin test for shiga toxin • PCR to test for toxin genes • Serology for previous O157 infection (not available in SG)

Microscopy	Bacteria	From	Virulence & Epidem	Clinical Presentation	Approach & Treatment
NLF	***Shigella*** ***dysenteriae*** ***flexneri*** ***sonnei*** ***boydii***	Not normal flora. Fecal-oral spread fr other humans, via fomites / flies	Outbreaks common in primary schools, residential institutions. Low infective dose	• Dysentery (esp *Shi dysenteriae*): frequent passage of blood-stained mucopurulent stools • Milder diarrhea (esp *Shi sonnei*) • *Shi. dysenteriae* type 1 produces Shiga toxin (like VTEC toxin) and can cause HUS	As above
LF	***Klebsiella sp.***	Normal gut flora		• UTI • Friedlander's pneumonia: severe bronchopneumonia + abscess • Hospital acquired infection	
NLF, swarm on blood agar	***Proteus sp.***	Normal gut flora		• UTI • Renal calculi: produces urease, alkalinizes urine.	

Resistance:
- HAI coliforms often multi R
- Cannot use penicillins due to beta-lactamase
- Cephalosporins (ceftriaxone): stable to beta-lactamase but now bact R w EBSL (extended spectrum beta lactamases)

Treatment:
- Co-amoxiclav, piptazobactam: labile penicillin plus beta-lactamase inhibitor
- Aminoglycosides: gentamycin, amikacin (toxic! therapeutic drug monitoring nec)
- Ciprofloxacin (R is a problem)
- Imipenem
- Combination therapy if unsure.

PSEUDOMONADS

Gram – rods, oxidase +

MICROSCOPY	BACTERIA	FROM	VIRULENCE & EPIDEM	CLINICAL PRESENTATION	APPROACH & TREATMENT
Aerobic, non-lactose /glucose fermenting Prod green difusable pigment	***Pseudomonas aeruginosa* (PAE)**	Moist env: water, soil, plants, animals. Biofilms on catheters Contaminated fluids & instruments	**Epidemeology:** Rare in healthy people, primarily nosocomial, esp w • Cystic fibrosis, ICU, burns, cancer patients • Use of Ventilators, bronchiectasis, IDC • Obstruction to biliary / urinary / sinus sys	**Hospital acquired:** • UTI (esp with surgery / IDC / retention) • Pneumonia (esp with ventilator) • Septicaemia. Can do other inf too. • Ecthyma gangrenosum - hemorrhagic, necrotic, ulcerating skin lesions • GIT infection, necrotising enterocolitis • Skin & soft tissue inf: wounds, burns, catheter **Community acquired** • Malignant otitis externa (painful swollen ear, systematically unwell), chronic supprative otitis media • Eye inf: keratitis, due to improper care of soft contact lens. Can lead to loss of eye • Skin: folliculitis, nail inf	**Treatment** Naturally multi-R so check sensitivity: • Piperacillin (anti-pseudomonal) • Carbapenems: imipenem • 3G cephalosporin: ceftazidime, cefepime • Aminoglycosides: gentamicin, amikacin • Quinolones: ciprofloxacin Contact lens infections: must cover pseudomonas to avoid loss of eye! **Prophylaxis:** ciprofloxacin for neutropaenic patients
	Stenotrophomonas maltophilia	Nosocomial, esp in units with heavy carbapenem use			Very R, inc carbapenems & aminoglycosides. Use co-trimoxizole / levofloxacin
Wrinkled colonies No diffusable pigment (or serodiagnosis)	***Burkholderia pseudomallei* ***	Soil & surf waters in SEA & N Aust Via inhalation & via skin abrasions	**Epidemeology:** at risk - • Diabetics Contact with soil	**Meliodosis** May present as pneumonia, abscesses, septicaemia. Sometimes high mortality • Highly varied, can affect any organ system. Presents diagnostic challenge, confused with TB • Incubation period can be days to years, latent infections may reactivate much later	Long antibiotic treatment • Drain abscesses • Ceftazidime / imipenem, 2 wk IV • Maintenance combi antibiotics, oral 6 mths
(multiple species)	***Burkholderia cepacia***	Selected for by multiple antibiotics	Typically in cystic fibrosis pt (poor drainage of secretions)	Serious & often terminal lung infections. Other patients & support groups often avoid them	

VIBROS

Short curved gram – rods, oxidase +, grows on TCBS (thiosulphate-citrate-bile salts-sucrose)

MICROSCOPY	BACTERIA	FROM	VIRULENCE & EPIDEM	CLINICAL PRESENTATION	APPROACH & TREATMENT
Yellow colonies on TCBS (sucrose fermentation)	***V. cholerae** ** (O1 & O139)	Fecal-oral transm, esp disaster areas. Contamination of water & foods esp by sewage or due to poor sanitation	Cholera toxin irreversibly activates enterocyte adenyl cyclase, causing cAMP overproduction, salt & water secretion instead of uptake O1 & O139 cause epidemics	**O1 & O139 serotypes - cholera** • Profuse diarrhoea with rice-water stools (fishy odour) • Dehydration & death, esp in children <5 yo • Usually no abdominal pain or fever Other serotypes cause less severe diarrhoea + cramps.	**Treatment** • Oral rehydration salts or IV • Antib (tetracyclin, ciprofloxacin) reduce severity of diarrhoea & shorten duration of cholera excretion **Vaccine:** against type O1 available
Green colonies on TCBS (non ferm)	***V. parahaemolyticus***	Grows in salt water. Fr eating undercooked / raw shellfish		**Food poisoning:** • Acute onset diarrhoea (explosive & watery or frank dysentry like) • Cramps & sometimes low-grade fever • Seldom severe fluid loss (cholera) or significant intestinal tissue damage (shigellosis)	Usu self-limiting, antibiotics do not alter clinical course
	V vulnificus	Grows in salt water Eating contaminated seafood Seawater exposure on wounds		**Ingestion:** • Diarrhoea (rare) • Septicemia with high fever & hypotension, 50% mortality: in immunocompromised patients, esp elderly males with alcoholic liver damage **Wound infection:** cellulitis, edema, erythema, life threatening necrotising fascitis	Aggressive wound debridement or amputation Combinations of doxycyclin, ceftazidime, ciprofloxacin.

FASTIDIOUS GRAM – RODS

HACEK group: fastidious gram - associated with endocarditis
- *Haemophilus spp.*
- *Actinobacillus actinomycetemcomitans* (now *Aggregatibacter*)
- *Cardiobacterium hominis*
- *Eikenella corrodens*
- *Kingella kingae*

MICROSCOPY	BACTERIA	FROM	VIRULENCE & EPIDEM	CLINICAL PRESENTATION	APPROACH & TREATMENT
Grow poorly on blood agar, better on chocolate agar. Req X + V factors	***Haemophilus influenzae***	Throat carriage common Transmission: resp droplets or close contact	**Encapsulated strains** (a-f) • b is most common • Virulence factor: evade phagocytosis • Usu young children (imm sys cannot handle capsule)	**Invasive disease** • Meningitis • Acute epiglottitis & resp difficulty (emergency): do not take throat swab as it can provoke spasm • Septicaemia • Pneumonia • Cellulitis, Osteomyelitis, Septic arthritis	**Treatment** • Ceftriaxone • Beta lactamase common, R to amoxycillin / ampicillin **Vaccine:** Conjugate vaccine for Hib Chemoprophylaxis & Hib vaccine for contacts
			Non-encapsulated strains With HiB vaccination, other strains / non-encapsulated becoming more prominent	**Invasive:** • In neonates: septiaemia, meningitis • In elderly (esp with comorbids): pneumonia **Non-invasive** • URTI (otitis media, sinuisitis), COPD exacerbations • Conjunctivitis (+ overwhelming speticemia in 1 strain – brazilian purpuric fever)	
Chocolate + X only "Shoal of fish" app	***Haemophilus ducreyi***	STD		**Chancroid:** painful genital ulcers + inguinal lymphadenopathy, destruction of genitalia & promote HIV transmission	Many.
Mercury drop colonies	***Bordetella pertussis & B. parapetussis***	Resp droplets	Usu affects young children	**Whooping cough** • Initial phase (catarrhal) looks like many other resp inf • Paroxysmal cough: continous cough + final whoop • Complications: respiratory or CNS	**Diagnosis:** Per-nasal swab fr wire into nasopharynx. Culture or PCR **Treatment**: Erythromycin if given early. If late, antibiotics little effect. **Vaccine:** yes, acellular / whole cell
Donovan bodies in macrophages	***Klebsiella (Calymmatobacterium) granulomatis***	STD		**Granuloma inguinale** (dovanosis): ulcerative genital lesions, slowly enlarging with prominent granulation tissue, scarring. Spreads to inguinal region, may cause fibrosis	
	Brucella spp.	Animal contact Infected food, untreated milk	Endemic in countries (e.g. Middle East) where not eliminated from wildlife	Varied, can be nasty, can have long incubation (months) • Acute febrile illness & pyrexia of unknown origin (PUO) • Chronic low-grade fever with malaise • Focal infections, joint & bone symptoms	**Diagnosis:** Blood cultures, serology **Treatment:** many, e.g. doxycyclin + streptomycin. Pasteurization of milk is impt!

Safety-pin appearance	***Yersinia pestis***	Rat flea bite or droplet spread btw men (if pneumonic)	Epidemic strain Worse in insanitary cond Bioterror	**Bubonic plague:** local lymph node infection (bubo) • Pneumonic plague if spread to lungs (allows droplet spread) • Septicaemia, often fatal (purpura on skin: black death)		Antibiotics will not prevent death once bacteraemia has exceeded a threshold: treat early
	Yersinia enterocolitica, Y. pseudotuberculosis			• Gastroenteritis, • Mesenteric lymphadenitis, terminal ileitis (like appendicitis) • Septicaemia, sometimes fatal		
	Legionella pneumophilia *& others*	Water: hot water supplies, air con, spa bath, nebuliser, O2 line humidifier. Via aerosols / drink	Only acute outbreak bacterial pneumonia Esp in elderly, smokers, immunosupp.	**Legionnaire's disease:** • Pneumonia (often severe) • Systemic disease, fever • Neurological signs (confusion, hallucination, etc) **Pontiac fever**: can also p/w brief influenza-like illness		**Diagnosis:** culture hard, • Urine antigen (serogroup 1 only) • Broncheoalveolar lavage (BAL) & immunofluorescent stain **Treatment:** erythromycin IV , fluoroquinolone, azithromycin
	Bartonella bacilliformis	Sandflies in S america		Oroya fever (high fever + severe anemia) Characteristic rash (verruca peruana)		
	Bartonella quintana	Body louse	Homeless people	**Trench fever:** fever, chills, malaise, myalgia, rash, shin pain	B. quintana & henselae can, in AIDS patients, cause • Bacillary angiomatosis (prolif vascular lesions, e.g. on skin) • Bacillary peliosis (affects liver &spleen) Also unusual endocarditis	
	Bartonella henselae & Bartonella clarridgeiae			**Cat-scratch disease**: fever + painful persistent reg lymphademopathy		
	Pasteurella multocida	Animal bites		Local infection at bite site Other infection possible		Penicillin (but many bites polymicrobial, need wider cover)
	Francisella tularensis	Athropod bite, animal contact, contam food/water, bioterror		Tularaemia: • Local infection at bite site / eye, lymph node inf • Pulmonary or typhoidal disease • Septicaemia		
	Acinetobacter baumanii & others	Environment, normal skin flora	Big outbreaks may occur	Nosocomial infections in immunocompromised, • e.g. pneumonia		Often multiply resistant, sometimes completely resistent.
	Bacterial vaginosis (not single organism)		Disturbance of normal bact (many lactobacilli)	Thin, smelly vaginal discharge (alkaline, pH > 4.5) Pregnancy complications		**Microscopy:** Clue cells (epithelial cells + small adherent bact) **Treatment:** metronidazole

AEROBIC GRAM + RODS

MICROSCOPY	BACTERIA	FROM	VIRULENCE & EPIDEM	CLINICAL PRESENTATION	APPROACH & TREATMENT
Grow on selectv Tinsdale's media Chinese letters app on gram stain Toxigenic strains prod precipitation line on Elek plate	***Corynebacterium diptheriae***	Asymptomatic carriers, spread by resp droplets Endemic in some countries	Diptheria toxin: enters cytosol & switches off prot syn Infects throat, nose, larynx, trachea, skin.	**Diptheriae** • Pseudomembrane formation, airway obstruction • Inflammation, bull neck • Toxin causes myocarditis, arhythmia, heart failure • Toxin causes nerve damage, muscle weakness & paralysis inc resp muscles (non toxigenic strains occasionally cause pharyngitis, skin abscess, invasive inf)	**Treatment** • Clinical diagnosis as lab takes several days • IV antiserum to neut toxin • Erythromycin • Treat complications **Prevention:** • Vaccination with diptheria toxoid • Isolation of carriers
	Corynebacterium ulcerans			Throat lesions Diptheria-like systemic illness	
	Corynebacterium jeikeium	Nosocomial inf		Opportunistic infections, e.g. of wounds, implanted devices e.g. valves, IV lines	Often multi-R
	Cornebacterium minutissimum			Erythrasma (brown, scaly skin patches in skin fold areas, floresce coral pink with Wood's lamp)	
Large gram + rod	***Bacillus anthracis***	From animals. Resistant spores. Introduced into skin, inhalation, ingestion	Antiphagocytic capsule Toxins: protective antigen, edema factor, lethal factor (lyses macrophage) Biological warfare weapon	**Anthrax** • Cutaneous anthrax: central black area (eschar) surrounded by vesicles & edema • Respiratory anthrax fr inhalation: rapidly fatal • Intestinal anthrax fr ingestion: also fatal. • Septicaemia & death	**Treatment** • Penicillin & ciprofloxacin. • If used as biowarfare, multi-R strains may deliberately be used • Cephems don't work Vaccines available in limited quantities
	Bacillus cerus	Food poisoning (often fried rice)	Spores survive boiling & when cooked rice left to stand, germinate & secrete heat-stable toxin	**Food poisoning** • Rapid onset (6h): vomiting (due to preformed toxin) • Slow onset (8-24h): diarrhoea, abdominal pain (enterotoxins made in intestine) Rare: wound inf, invasive inf, post-traumatic ophthalmitis	
Short gram + rod (can mistake as coccus)	***Listeria monocytogenes***	Food-bourne	Can multiply at 4 deg C An intracellular organism	• Febrile gastroenteritis • Pregnancy: abortions, premature labour, still birth • Baby w granulomatosis infantisepticum (born severely ill with multisys inf), early-onset neonatal listeriosis or late-onset neonatal meningitis • Meningitis & endocarditis in immunosuppressed pts	**Treatment:** Ampicillin +/- gentamicin • R to cephalosporins • Empirical meningitis tx in susceptible pax must cover Listeria. Cephalosporins treats most other meningitis bact (E coli, N meningitidis, Hib, S agalactiae) but not listeria

Microscopy	Bacteria	From	Virulence & Epidem	Clinical Presentation	Approach & Treatment
Branching beaded gram + filaments (like A. israelli)	***Nocardia spp.***	Soil, env	Opportunistic: AIDS pt, immunosuppressed pt	• Lung inf • Disseminated inf, abscesses inc in brain • Madura foot: chronic destructv inf in tropical countries (many bact or fungi can cause this)	**Treatment:** Long course of co-trimoxazole
	Lactobacillus	Mouth, gut, vaginal flora		• Role in dental caries • Good probiotics!	
	Erysipelothrix rhusopathiae		Usu in pple who handle meat / fish	Erysipeloid: cellulitis with blue-red discolouration (not same as erysipelas)	
	Arcanobacterium haemolyticium			Sore throat (rare) Skin rash with scarlet fever	
	Rhodococcus equi	Animals		Lung infection in immunocompromised / AIDS	

CLOSTRIDIUM

Gram + rods, obligate anaerobes. Sporing.

MICROSCOPY	BACTERIA	FROM	VIRULENCE & EPIDEM	CLINICAL PRESENTATION	APPROACH & TREATMENT
Opaque zone on Nagler plate, but not with antitoxin	***Clostridium perfringens***	Human feces, skin. Injury • War wounds, RTA • Vascular disease • Surgery on bowel or biliary tract Bloodstream infection possible if underlying disease	Lecithinase (alpha toxin): breaks down lipids & cell mem C. septicum in bloodstream is associated with underlying CA	**Gas gangrene** (other clostridia cause this too) • Fr introduction of spores into area with poor blood SS • Clostridial myonecrosis • Crepitus on pressing tissue, or gas on X rays. • Severe pain, swelling, discolouration, fluid-filled blebs • Systemically unwell, shock, drowsy. **Food poisoning** • Clostridial spores survive cooking, release toxins in gut • Abdominal cramps & diarrhoea in 12-24h • Diarrhoea in elderly patients • Pigbel: necrotising enteritis	**Treatment** • Early surgery for gas gangrene • Benzylpenicillin (+/- clindamycin) and wider cover. • Hyperbaric oxygen ? • Food poisoning: no need antib **Prevention:** • Prophylaxis with benzylpenicillin x 5d for predisposed pt, e.g. vascular dx + surgery • Avoid gluteal inj of adrenaline: skin spores inj + local vasoconstriction
Large terminal spores ("drumstick")	***Clostridium tetani***	Widespread: env, soil, farm animal feces, human gut. Traditional wound dressing with cow dung	Tetanospasmin (neurotoxin): block inhibitory stimuli fr UMN to LMN	**Spastic paralysis** • Lockjaw, risus sardonicus (sardonic grin) • Generalized spasm, opsithotonus (marked extension) • Respiratory muscle spasm can cause death.	**Treatment** • Wound debridement • Human tetanus IG (HTIG) to neut toxin • Antibiotic to kill any remainding clostridia • Resp distress: paralyze & ventilate Prophylaxis if pt w wound: above + vaccinate **Vaccination:** tetanus toxoid. Also for recovered patients, inf does not give immunity
Detect by animal inoculation	***Clostridium botulinum***	Preformed toxin in cont. (esp preserved) food, or wound infection	Botulnum toxin blocks ACh release at neuromuscular junc	**Flaccid paralysis** • Ptosis, diplopia, respiratory muscles affected • 'Floppy child syndrome' in young	**Treatment** • Antiserum (watch for hypersensitivity rx) • Intensive care inc ventilation
Toxin detection + GDH assay. PCR if inconclusive.	***Clostridium difficile***	Feces of few people Commensal inf	Ppt by antibiotic administration (clindamycin)	**Pseudomenbraneous colitis** • May have toxic megacolon, perforation • C. difficile associated diarrhoea • Often relapses after treatment	**Treatment** • Stop antib, PO metronidazole, vancomycin • Isolate patient and enhance inf control (spores survive normal alcohol hand rub)

NON SPORING ANEROBES

MICROSCOPY	BACTERIA	FROM	VIRULENCE & EPIDEM	CLINICAL PRESENTATION	APPROACH & TREATMENT
	General *Porphyromonas* *Prevotella,* etc.	Normal flora, even skin. Almost all colon bact.	Usually in mixed infections (aerobes & anaerobes), • usu fr endogenous flora • Usu w precipitatng cause (surgery / gut perf / DM)	Disgusting smell & watery pus (vs S. aureus thick pus) **H&N infections** • Vincent's infection (necrotising ulcerative gingivitis, can spread to tonsils to cause vincent's angina) • Dental sepsis • Abscess / cellulitis (if submandibular, Ludwig's angina) • Chronic ENT infections • Brain abscess **Systemic infections** • Pneumonia, lung abscesses, empyema usu aft aspiration • Peritonitis, abscess, wound infection aft appendicitis, surg, CA • Diabetic foot ulcers, anaerobic cellulitis & other soft tissue inf • Male & female genital tract • UTI rare: look for CA & fistula connecting to bowel • Osteomyelitis, septic arthritis (rare): w man/animal bite, punch, DM foot **Synergistic infections** • Necrotising fasciitis: S. pyogenes + anaerobes • Meleny's synergistic gangrene: ulceration (violaceous edge) usu at abdo op wound / colostomy site. S aureus + anaerobes • Fournier's gangrene: mixed scrotal infection	**Treatment** • Usu 'S' to metronidazole • Usu 'S' to penicillin' • Drainage of pus impt: dead necrotic tissue & other bact promote anaerobe • Sometimes prophylatic antibiotics after certain abdominal / gynae op.
Gram + branching filaments Slow growing: tell lab to not discard	***Actinomycosis israelii***	Normal flora	e.g. Teeth Inf aft mucosal dx/trauma or spontaneous	Slowly spreading inf, fibrosis and pus draining fr sinuses • Commonly cervicofacial, esp with dental prob • Thoracic: lung inf • Abdominal: diseased appendix / colon • Pelvic: e.g. with IUD use	**Diagnosis:** gram stain 'sulphur granules' (actually colonies) inside pus **Treatment:** R to metronidazole • Use penicillin / amoxicillin for 2-3mths
	Fusobacterium necrophorum			Necrobacillosis, e.g. life threatening **Lemierre's disease**: • severe sore throat leading to septicaemia, abscesses • septic jugular thrombophlebitis in jugular vein	**Treatment** • Drain pus • Penicillin
	Bacteriodes fragilis	Colonic flora		Often abdominal infections. Most common non-sporing anaerobe causing bacteremia	R to penicillin (beta-lactamase) S to metronidazole

MYCOPLASMA

Small bacteria, little/no peptidoglycan cell wall. NOT obligate intracellular

MICROSCOPY	BACTERIA	FROM	VIRULENCE / EPI	CLINICAL PRESENTATION	APPROACH & TREATMENT
No peptidoglycan: cannot gram stain	***Mycoplasma pneumoniae***	Often detected in man		**Respiratory tract infections** • Usu mild ("walking pneumonia") • Paroxysmal cough (confusion w whooping cough) • Patchy opacity on XCR • Atypical pneumonia (mycoplasma, chlamydia, legionella) • Severe infection in immunocompromised & sickle cell pt • Complications: Stevens-Johnson syn (mild form of toxic epidermal necrolysis), rash, joint pains, encephalitis, meningitis, hemolytic anemia, myocarditis/pericarditis	**Diagnosis** • Serology: cold agglutinins, ppt at 4 deg C • Specific serology (complement fixation test) & IgM assays to show rise in titre from acute to convalescent phase. More sensitive in children than adults **Treatment:** R to beta-lactams, no cell wall • Erythromycin, or macrolides, or tetracycline, or resp quinolone, Q2-3wks
Fried-egg colonies	***Mycoplasma hominis***	Possibly normal flora, uncertain.	Often polymicrobial	**Urogenital infections** • Non-gonococcal / post-gonococcal urethritis (NGU/PGU) • UTI and renal calculi • Bacterial vaginosis • Ascending infection, pelvic inflammatory disease • Post-abortion & post-partum fever • In neonates – meningitis, Also inf & septicaemia in the immunocompromised, e.g. transplant pts, congenital hypogammaglobulinaemia pts	
Protrusion looks like genitals	***Mycoplasma genitalium***				
	& others				

CHLAMYDIA

Small bacteria, little/no peptidoglycan cell wall. Obligate intracellular pathogens.
Elementary body (EB) enters host cell, reproduces as reticulate body (RB). New EB prod & released, EBs are infectious

MICROSCOPY	BACTERIA	FROM	VIRULENCE / EPI	CLINICAL PRESENTATION	APPROACH & TREATMENT
Almost no peptidoglycan	***Chlamydia trachomatis*** *Serovars A, B, Ba, C*	Fingers Flies Fomites	Third world Inf of poverty	**Trachoma** • Eye infection, pannus (cornea clouding), chronic inflammation & scarring, blindness	**Diagnosis:** serology • Chlamydial complement fixation test (CFT): genus-specific only. • Micro-immunofluorescence(MIF): Species and serovar-specific • Usu done only for more invasive inf, e.g. atypical pneumonia. Rise in titre from acute to convalescent samples proves cause.
	Chlamydia trachomatis *Serovars L1, L2, L3 (LGV biovar)*	STD	Tropics & subtropics	**Lymphogranuloma venereum (LGV)** • Primary lesion: small papule, vesicle • Inguinal lymphadenopathy (suppurate, discharge through sinuses) • Females & homosexual men - Proctitis & bloody anal discharge due to perirectal gland suppuration • If chronic, rectal stricture or genitalia elephantasis	
	Chlamydia trachomatis *Serovars D-K* *(A-K also known as occulogenital biovar)*	STD	Developed countries	**Males** • Non-gonococcal & post-gonococcal urethritis • Proctitis in homosexuals **Females** • Asymptomatic inf of endo-cervical canal • Nucopurulent cervicitis / urethritis, vaginal discharge, proctitis • Ascending infection: acute salpingitis / pelvic inflammatory disease, fitz-hugh-curtis syn, ectopic pregnancy, infertility. • Opthalmia neonatorum (dvps in 10d vs 3-5d in gonorrhoea) **Both** • Reiter's syn: autoimmune rx fr cross reactivity (commoner in men) - Reactive arthritis + conjunctivitis/uveitis + urethritis/cervicitis • Adult inclusion conjunctivitis (paratrachoma): inf own eyes via fingers	**Diagnosis:** • Culture is difficult • Antigen detection, immunofluorescence • Molecular methods: PCR, NAAT (nucleic acid amplification techniques) **Tratment:** Opthalmia neonatorum: systemic treatment with erythromycin to prevent pneumonia **Prevention:** STD measures, screening of high-risk groups, condoms, contact tracing
	Chlamydophilia psittaci	Birds		Flu-like illness, atypical pneumonia Inf may disseminate to many other sites inc brain, meninges, joints Rare cause of culture-negative endocarditis.	**Diagnosis & treatment:** See C. trachomatis **Prevention:** Quarantine infected birds
	Chlamydophilia pneumoniae	Community		Mild pneumonia (reinfection / chronic inf possible in older pt) May contribute to atherosclerosis ?	

RICKETTSIA, COXIELLA & COUSINS

Small gram –ve. Obligate intracellular pathogens

MICRO	BACTERIA	FROM	VIRULENCE / EPI	CLINICAL PRESENTATION		APPROACH & TREATMENT
	Rickettsia typhi	Typhus gp: flea	Infects endothelial cells of BV **Epi:** Endemic in SG. Esp foreign workers living in poor rat-infested cond & returning travellers	Murine typhus	**Typhus / Spotted fever** • Pyrexia of unknown origin (PUO) • Headache, muscle pain • Skin rash possible (can be macular, papular, petechial, or hemorrhagic) • Eschar (black ulcer) at site of primary inf • Meningoencephalitis possible in RMSF	**Diagnosis:** Difficult • Weil-Felix test no longer method of choice • Serology: but treatment may delay appearance of antibodies by wks • Part of ddx for PUO in singapore **Treatment:** Doxycycline (but R has been detected in N thailand)
	Orientia tsutsugamushi	Larval mite (chiggers)		Scrub typhus		
	Rickettsia rickettsii	Spotted fever gp: tick		Rocky mountain spotted fever		
	Rickettsia prowazeki	Typhus gp: louse (bact kills vector) Reservoir: man	Overcrowded reg w poor hygiene	**Epidemic typhus** • Severe form of the above – fatality 10-50% • BV damage leads to hypotension & organ hypoperfusion • Brill-Zinsser dx (recrudescent dx): inf may reactivate aft many yrs. 1 case can restart an epidemic		**Control:** Delousing susceptible pop
Morula in WBC cytosol (inclusion w bact)	***Ehrlichia chaffeensis*** ***Ehrlichia ewingii*** ***Anaplasma phagocytophilius***	Tick bites	Infects WBC • 1, 2, 4: mono/macrophage • 3: granulocytes	Fever, rash, multi-system disease.		**Diagnosis:** Serology **Treatment:** Doxycycline
	Neorickettsia sennetsu	Raw fish (? w infected flukes)		Glandular fever (infectious mononucleosis) like illness: chills, fever, enlarged cervical LN, usu mild		
	Coxiella burnetti	Many animals: eg sheep, cattle, goats. Shed bact in urine, faeces, milk, esp birth pdts	Forms resistant spore-like str Replicate inside acidified vesicle in macrophages **Epi:** common in some areas, assoc w farming communities	**Acute Q fever** • Many asymptomatic / minor flu-like illness • Pyrexia of unknown origin (hence 'Q' fever) • Pneumonia • Hepatitis • Infected pregnant mothers may affect child **Chronic Q fever:** culture negative endocarditis, rare cholecystitis		**Diagnosis:** Serology **Treatment:** • Doxycycline + rifampicin • Treatment of endocarditis difficult • Idea: Hydroxychloroquine (weak base) to raise phagolysosome pH, in which bact replicates.

SPIRAL BACTERIA

Note: Spirochete refers to Treponema, Borrelia, Leptospira only. Not Spirillum, Camphylobacter, Helicobacter

MICRO	BACTERIA	FROM	VIRUL / EPI	CLINICAL PRESENTATION	APPROACH & TREATMENT
Spirochetes on dark ground illumination	***Treponema pallidum***	STD, needlestick injury		**Primary syphilis** • Chancre (ulcer, usu painless) on genitals, cervix, mouth, anus, or fingers. • Local LN enlargemt • Increased chance of HIV infection **Secondary syphilis**: spread throughout body. V infectious! • Rash (many forms) also involving palms & soles (unlike other rash) • Mucous patches on mucous membranes, snail-track ulcers • Condylomata lata: Warty lesions on anus, genitals, warm moist areas • Generalized LN enlargement, fever, etc • Potential acute meningeal involvement **Latent:** Asymptomatic. Relapse more common in early latent syphilis than late. **Meningeal syphilis:** chronic meningitis (headache, nausea, neuro signs), usu in first year **Neurosyphilis (tertiary syphilis)** • Meningovascular syphilis: CNS disease (headache, vertigo, psy), stroke • General paresis (general paralysis of the insane): madness & weakness, then dementia • Tabes dorsalis: demyelination of pos columns of spinal cord & dorsal root. Loss of proprioception, ataxic gait, lightning pains. Results in foot ulcers or chronic joint damage (Charcot's joint) secondary to loss of sensation • Sign - Argyll Robertson pupils: small irreg pupils, react to accomodation but not light **Gummatous syphilis (tertiary):** gummatous necrotic lesions (gumma) on skin, mucous membranes, bone, other organs **Cardiovascular syphilis (tertiary):** Thoracic aortitis, resulting in • Narrowing of origin of LCA & RCA: angina, MI • Aortic valve ring stretching: aortic incompetence • Aortic aneurysm, can bulge through skin. Visible on CXR **Congenital syphilis:** Crosses placenta to result in • Abortion • Early lesions resembling secondary syphilis, then tertiary syphilis lesions • Huchinson's triad: CN8 deafness, interstitial keratitis (corneal clouding, blindness), Hutchinson's teeth (notched incisors) Syphilis is a great imitator: if symptoms cannot be explained, suspect suphilis	**Diagnosis:** Cannot culture. • Early stages: DGI, except for mouth ulcers which has other treponemes • Serology in later stages as nearly all treponemes eliminated • Always repeat screens • Other non-STD treponema (yaws, pinta, bejel / endemic syphilis) fr tropical reg can give + results: take a travel history **Serology:** • Non-specific tests: VDRL (veneral dx ref lab) & RPR (rapid plasma rgt) • Specific tests: T pallidium haemagglutination (TPHA) , particle agglutination (TPPA), florescent T antibody (FTA). Line & enzyme immunoassay (EIA/LIA) • Sp tests are more sensitive, non-sp tests can give false + or -. • Results may – in early primary syphilis • VDRL/RPR titres decrease with treatment response **Treatment:** Benzylpenicillin • May give Jarish-Herxheimer rx: large no. of bact killed at once triggers systemic imm response. • Get STD physician to manage follow up, difficult serology, detection of asymptomatic neurosyphilis. **Prevention:** • Antenatal & blood donor screening • Screen STD pts: pts with 1 STD likely to have another. • Contact tracing

MICRO	BACTERIA	FROM	VIRUL / EPI	CLINICAL PRESENTATION	APPROACH & TREATMENT
No need DGI, can see on blood smear	***Borrelia recurrentis***	Body lice of humans	Africa S america	**Relapsing fever:** • Fever alternating with afebrile intervals • Fever due to antigenic variation, no fever when the immune system catches up. • Mortality up to 40	**Diagnosis:** Spirochete on blood film **Treatment:** Doxycycline. • May give Jarish-Herxheimer rx
	Borrelia duttoni	Tick, fr rats	Worldwide		
	Borrelia burgdorferi	Hard tick in outdoors. Many animal reservoir sp	Europe, US, China, Aust Japan	**Lyme disease** • Stage 1: Erythema chronicum migrans (ECM): rash beginning at site of bite, then spreading out in a ring. May have assoc systemic disease • Stage 2: Wks to mths later – Neuro, CVS, muscuskeletal dx, arthritis • Stage 3: Mths to yrs later – Chronic skin, jt, neuro dx	**Diagnosis:** Serology, subjective **Treatment:** Doxycycline in early stages. Later stages depends
	Leotospira interrogans	Urine of rats, animals. Via contact w water	Farmers, sewage workers, water game esp tropics	**Leptospirosis** • Bacteraemic leptospirosis: flu-like fever, muscle pain, conjunctival congestion • Immune phase (due to imm resp): meningeal sym (headache, vomit, aseptic meningitis) • Weil's disease (icteric leptospirosis): jaundice, hemorrhages, renal failure, conjunctival congestion. May be fatal.	**Diagnosis:** DGI, culture possible but difficult. Usually serology **Treatment:** Benzylpenicillin
	Spirillum minus, Streptobacillus moniliformis	Rat bites		**Rat bite fever:** local lesion, local lymphadenopathy, fever, rash. S. moniliformis also causes haverhill fever from drinking contaminated milk/water	**Treatment:** Benzylpenicillin
Gram – spirals Grows in micro-aerophilic cond Oxidase +ve	***Campylobacter jejuni***	Fecal-oral transmiss Poorly-cooked inf poultry	More common	**GIT infections** (Incubation 1-7 days, initial flu-like prodromal illness possible) • Abdominal pain, often severe (suspected appendicitis) • Diarrhoea: sometimes with frank blood (local haemorrhage, can be severe) **Complications** • Reactive arthritis • Guillain Barre syn: ascending neuropathy, symmetric weakness starting fr LL. May affect lower CN, leading to ventilatory failure, loss of autonomic function	**Diagnosis:** Culture on selective media to suppress normal flora, in micro-aerophilic cond at 42 deg **Treatment:** Usu self-limiting. Hydrate. • Severely ill pt: erythromycin, ciprofloxacin • Eliminate source, safe food handling
	Campylobacter coli		Rarer		
	Campylobacter fetus			Occasional diarrhoea Septicaemia in immunocompromised.	
	Helicobacter pylori	Fecal-oral, oral-oral ? carriage	Prod urease to inc pH & erode mucosa	**Inf of gastric mucosa** • Acute inf inapparant, sometimes abdo pain, flatulence, nausea, bad breath. • Chronic active gastritis: peptic ulceration, gastric cancer, gastric MALT lymphoma	**Diagnosis:** • Urea breath test: bact split urea to release $^{14}CO_2$ • Fecal antigen test. • Biopsy, then culture, microscopy, rapid urease test **Treatment:** Multiple agents, long-term
	H. cinaedi, fenneliae			Proctitis in homosexual men	

MYCOBACTERIA

Waxy cell wall with complx lipids (mycolic acids), resistant to drying/env factors & pronounced immunological activity
Acid fast bacilli on Ziehl-Neelsen (heat drive fuschin into cells) or Auramine (florescent)

MICRO	BACTERIA	FROM	VIRUL / EPI	CLINICAL PRESENTATION	APPROACH & TREATMENT
Slow growing • No yellow pigment on Middlebrook agar • X grow at 25 & 41 C • X grow on p-nitrobenzoic acid • Nitrate positive	***M. tuberculosis cplx*** ***M. tuberculosis*** ***M. africanum*** ***M. canetti*** ***M. bovis*** ***M. microti***	Resp droplet	Obligate pathogens (never contaminant): • Overcrowding: prisons • Poverty: homeless • Poor nutrition • Immunosuppressed: elderly, drug/alcohol use, HIV/DM etc	**Tuberculosis** (see clinical notes)	**Diagnosis:** culture takes up to 8 wk • Decontaminate specimen • Solid: Lowenstein Jensen (LJ) or Middlebrook 7H10 agar • Broth media (automated) • Rapid PCR & other molec methods
AFB in dense clumps within macrophages	***M. leprae***	Close & prolonged contact (infectivity is low)	Obligate intracellular AFB Paucibacillary: 1-5 skin lesions Multibacillary: ≥6 skin lesion	**Leprosy:** Chronic granulomatous inf nerves Schwann cells • Affect peripheral n Schwann cells: Nerve damage: paralysis, anesthesia, trophic ulcers, Charcot joint (neuropathic joint dx) • Affects skin: hypopigmented & hypoaesthetic skin lesions • Can be tuberculoid, lepromatous, or borderline. **Tuberculoid leprosy:** strong Th1 + cell mediated response • 1-2 hypopigmented skin lesions • Thickening of peripheral nerves (ulnar, peroneal, median, accessory n) – but biopsy rarely shows M. leprae **Lepromatous leprosy:** no cell mediated response, mainly Th2 • Mycobacteremia; biopsy shows undiff macrophage ++AFB • Edema of affected tissue • Collapse of nosebridge & facial lip swelling (leonine facies) • Spread: nasopharyngeal mucosa, eye, muscles, testicles, marrow • Highly infectious due to nasal discharge	**Examination** • Do neuro exam: sensory + motor • Palpate nerves for tenderness / thickening **Diagnosis:** • Cannot culture in vivo (except mouse footpad or armadillo) • Biopsy+histo: skin, nerve, retina • Examine slit skin smears for AFB **Treatment:** • Paucibacillary: Rifampicin monthly + Dapsone daily x6mo • Multibacillary: Rifampicin monthly + Dapsone & Clofazimine daily x2yo

MICRO	BACTERIA	FROM	VIRUL / EPI	CLINICAL PRESENTATION	APPROACH & TREATMENT
Photochromogen	***M. kansasii*** ***M. malmoense*** ***M. xenopi***	Env, soil & water		**Pulmonary opportunists** in pt w lower resp tract abnormalities (e.g. bronchiectasis, COPD)	Non-tuberculous mycobacteria (NTM) may be contaminants; NTM found may not be causing disease **Diagnosis:** based on • Photochromogens: prod pigment in light only • Scotochromogens: prod pigment in dark and in light • Nonchromogens: unpigmented **Treatment:** difficult and prolonged, R to many antibiotics. Usu combis
	M. avium intracellulare cplx ***M. haemophilum*** ***M. cookei*** ***M. hiberniae***			**AIDS-related opportunists**	
Photochromogen	***M. marinum*** ***M. ulcerans***		Fishmongers S. america	**Skin pathogens:** • M. marinum causes fish tank granuloma • M. ulcerans causes Buruli ulcer	
Rapid growers: grow on LJ agar in 1 wk	***M. fortuitum*** ***M. abscessus*** ***M. chelonei cplx***			**Injection associated** Contaminated injection fluids • Bacteraemias in IV drug users • Skin inf due to contaminated injection fluids (e.g. DM insulin)	

M2 FUNGI

Nigel Fong 2012

General principles

Fungi are particularly bad for the immunocompromised! For direct examination, KOH helps to dissolve keratin. In culture, fungi grow more slowly than bacteria. Use Sabouraud's agar, +/- supplements & antibiotics (e.g. chloramphenicol) to select for fungi. Moulds (filamentous form) can produce identifiable structures but yeasts look alike.

A| Candida

By far the most common yeast infection. Candida are ubiquitous in the environment, and also normal commensals in human skin, GIT, and female genital tract. Often a contaminant!

Mycology: Usually C. albicans, which produces germ tubes within 2 hours when incubated in serum. Many other species

Predisposing factors

- Antibiotics, esp prolonged use of broad spectrum antibiotics
- Catheterization, IV drug users, total parenteral nutrition
- Immunodef: Neutropenia, qualitative neutrophil defects, depressed humoral imm, pregnancy, diabetes, HIV
- Age: young or old

Superficial candidal yeasts: generally moist regions

- Oral (mouth & tongue)
- Genital: vagina, penis
- Intertrigo (skin folds)
- Finger nails (onychomycosis)
- Chronic mucocutaneous caididiasis due to genetic defect

Systemic & deep candidosis

- Candidaemia. May present as fever, without localizing signs.
- Hepatosplenic candidasis
- Pericarditis, Myocarditis (ECG changes non-specific), endocarditis. Especially with prosthetic valves, superimposed on bacterial endocarditis
- Candidal pneumonia (rare), via endobronchial or haematogenous spread.
- UTI, especially with IDC. Ascending infection (or haematogenous spread) can involve the kidney, forming renal abscesses etc.
- Eye: ocular involvement
- Peritonitis, esp after bowel surgery
- Bone & joint
- CNS

B| Systemic mycoses

1. Cryptococcosis
Cryptococcus neoformans, C. gattii

Mycology: Encapsulated yeasts (visible on India Ink preparation). Cryptococcal antigen test also available.

Epidemeology: Found worldwide. Frequently found in excreta of birds esp pigeon, associated with eucalyptus trees. Cause disease if inhaled. No spread between humans. Infections usually in immunocompromised including AIDS, but also may occur in normal individuals.

Presentation:

- Meningitis, often subtle and slowly developing. Cranial nerve damage.
- Cryptococcoma in CNS or lung. Often mistaken for cancer, can be asymptomatic
- Pneumonia
- Prostate
- Skin: granuloma

2. Aspergillosis.
Many species cause disease; commonest is *Aspergillus fumigatus*.

Epidemeology: Ubiquitous in environment, transmission by airbourne spores; more with construction activity.

Presentation:

- Allergic response (asthma-like symptoms). In one form of allergic disease, fungus colonizes the airways - allergic bronchopulmonary aspergillosis
- Aspergilloma (fungus ball) in abnormal lung cavity e.g. TB cavity
- Invasive aspergillosis can disseminate to many other tissues. Endocarditis is possible. Esp in severely immunocompromised, e.g. neutropaenic, immunosuppressed, chemotherapy etc.

Diagnosis:

- Microscopy: KOH prep on sputum, biopsy of lung etc.
- Serology: *Aspergillus* precipitins (an antibody test) usually detected in allergic forms and fungus ball
- Serial measurement of circulating galactomannan (antigen produced by *Aspergillus* spp)

3. Dimorphic fungi

The dimorphic fungi grow as hypae at 25C, and as yeasts in the body. Geographical distribution varies: occurs in the tropics, and the Americas. Usually start with inhaled spores causing lung infection; infection spreads through body (dissemination) in some individuals, particularly in those with AIDS but sometimes in those with normal immune systems.

Penicillium marneffei

- **Epidemeology:** Fungus of bamboo rats. An opportunistic infection in AIDS patients in SE Asia, particularly Thailand.
- **Mycology:** characteristic red pigment diffusing into agar. Yeast-like bodies inside the patient's macrophages
- **Presentation:** Usually fever, weight loss, anaemia, often suggestive skin lesions (papules/abscesses)

Histoplasmosis:

- Epidemeology: Usu central/eastern USA. Occasionally there are imported cases from Indonesia. More prevalent where there is avian/bat excretement in soil
- Presentation: Very similar to TB.
- Primary infection & reinfection: pneumonitis, granuloma, cavities.
- Disseminated histoplasmosis can cause acute, sub-acute, or chronic symptoms
- Umbilicated papules, abscesses, pustules, ulcers on skin
- Often affects lungs, lymph nodes, liver, spleen, bone

Coccidioides immitis / Paracoccidioides brasiliensis

- Epidemeology: SW US, Central & South America. In semi-desert soil, esp sand storm
- Usually asymptomatic primary infection (possibly fever, chest pain, cough, weight loss, nodular lung lesion)
- Disseminated infection can be chronic or fulminant

Blastomyces dermatitidis

- Epidemeology: Mainly N america
- Can infect the skin (chronic/primary), lungs, or other organs

4. Mucormycosis (= Phycomycosis = zygomycosis)

Lower fungi, with broad aseptate hyphae.. For example, *Mucor* and *Rhizopus* species.

Tends to affect immunocompromised individuals. Presentation:

- Lungs may become infected.
- **Rhinocerebral mucormycosis**: spread from nose into paranasal sinuses, orbit, brain. Usually in an immunocompromised patient - often uncontrolled diabetes mellitus.

5. Pneumocystis jiroveci (carinii)

Causes opportunist infections of the lungs (pneumocystis pneumonia, PCP) in immunocompromised patients, particularly those with T cell defects including AIDS. Dissemination outside the lungs to other organs is increasingly recognized, especially in AIDS patients.

It **cannot be cultivated** and diagnosis depends on demonstrating it using special stains: e.g. **Grocott's silver stain or immunofluorescence.** These staining techniques seldom yield a positive result on sputum: examine bronchoalveolar lavage (**BAL**) or induced sputum sample. PCR diagnosis has been introduced in some centres.

Does not respond to conventional antifungals; use co-trimoxazole.

C| Subcutaneous mycoses

Rare in developed countries, usually imported from tropics/subtropics. Environmental fungi are **inoculated** deep into the tissues and grow there, deep to the skin. Commoner in men, and in rural environments, due to trauma, not wearing shoes etc. These infections are often chronic, progressive and deforming. Some are very hard to treat.

1. **Sporotrichosis**
Sporothrix schenkii

- **Epidemeology:** worldwide distribution. Found in soil, wood. Rare in Singapore, suspect in travellers.
- **Mycology:** dimorphic fungi.
- Local infection, ulcer & necrosis
- Spread along draining lymphatics causing further lesions.
- Rarely, disseminated infection occurs. Esp in alcoholics & immunocompromised

2. Chromoblastomycosis

- Epidemeology: puncture wound from injury with wood,
- Cauliflower-like lesions on lower extremities, forms a ring of papules growing outwards (while the centre heals), can last for decades

3. Mycetoma

- Epidemeology: numerous causative agents – fungi and Nocardia spp. Enter subcutaneous tissues from soil, plants, rotting vegetation etc. Common in tropical climate
- Madura foot (or on hands / LL): abscess formation, draining sinuses containing sulphur granules. Painless
- Can disseminate to muscles and bones.

4. Rhinosporidiosis

- Rhinosporidium seeberi found in fish & aquatic insects. Associated with swimming/working in stagnant water
- Polypoid masses with seropurulent discharge at nasal mucosa, conjunctiva, genitalia, rectum.

D| Superficial Mycoses

Common, worldwide, unpleasant but seldom very serious infections.

1. Dermatophyte infections (ringworm, tinea)

Dermatophytes invate skin & keratin in hair and nails.

Dermatophyte	Source	Presentation
Trichophyton rubrum	Human spread, wet floor.	Skin, nail (hair possible)
Trichophyton mentagraphytes var interdigitale		Athlete's foot (Tinea pedis)
Trichophyton mentagraphytes var granulare	Human, animals. Rare in SG	Skin, beard, hair
Microsporum canis	Animals	Scalp & hair (Tinea capitis)
Epidermophyton floccosum	Human spread	Groin & foot

Diagnosis:

- Examine skin scrapings, nail clippings, plucked hairs, hairbrush in KOH to clarify keratin and allow hypae to be seen.
- Characteristic macroconidia (big spores)
- Treatment can be instituted without species identification, however identification can help to look for source of fungus & help in case of antifungal resistance

2. *Malassezia furfur* & others

Mycology:

- Single celled. Yeast & hyphae seen together ('spagghetti and meatballs')
- Requires oil for growth.
- Normal flora in healthy individuals, can be transmitted between humans

Presentation:

- **Tinea (pityriasis) versicolour**: white/pink/dark spots, can be itchy
- Folliculitis, dandruff.
- Seborrhoeic dermatitis
- Peritonitis & septicaemia in newborn

3. Exophiala werneckii

- Tinea nigra – black smooth patch on sole/palm.
- Uncommon – usually travellers

4. Piedraia hortae

- Black piedra – hard, gritty, black nodules on scalp hair.

5. Trichosporon beigelli

- White piedra – white, soft nodules alone beard, axillary, pubic hair

6. Nattrasia mangifera (Scytalidium dimidiatum)

- Invades healthy nail & skin, transmitted with contact
- Not treatable with current drugs.

6. Otomycosis

- Aspergillus niger & others
- Fungal ball in outer ear

7. Keratomycosis (mycotic keratitis)

- Aspergillus, Candida & others
- Corneal ulcers
- Post-traumatic, post-surgical, contact-lens related infection
- Use antifungal eyedrop

Review pictures in lecture notes!

M2 VIROLOGY

Nigel Fong 2012

Respiratory tract viruses

Virus	Structure	Epi / Mech	Clinical Pre	Diagnosis / Treatment
Influenza *Orthomyxovirus*	Enveloped, w • Hemagglutinin (H): attachment • Neuraminidase (N): act on neuraminic acid receptors to bud out of cell • Type & strain specific designation: H (16) & N (9) • Imm is specific to H type 8 ssRNA segments; RNA segment recomb gives genetic reassortment	Influenza A - pandemics. B - epidemics. C is rare. **Antigenic shift:** recombination btw diff animal strains simultaneously inf same cell, resulting in major change & pandemics. **Antigenic drift:** spontaneous mut, minor changes.	**Flu:** upp resp tract epithelium desquamation & ciliary damage. Incubation 1-4 days. **Complications:** • Pneumonia: primary viral or secondary bacterial (S. pneumonia, H. influenza, S. aureus) esp in vulnerable pop • Myocarditis • Myositis • Reye syndrome: influenza B + aspirin in children can cause cerebral edema & fatty degeneration with high mortality **DO NOT USE ASPIRIN IN CHILDREN**	**Diagnosis:** isolation or antigen IF **Tx:** mostly symptomatic • Treat complications • Neuraminidase inhibitors: oseltamivir, zanamivir • Amantadine (inf A) • Infection control **Vaccine:** Inactivated vaccine of circulating strains for high risk groups. Renew yearly
Parainfluenza *Paramyxovirus*	Not segmented, no genetic recombination	4 serotypes w disease assoc (type 1 and 3 cause croup), but overlaps. Affects young children (small larynx lumen)	**Croup:** • Acute laryngotracheobronchitis • Cough, hoarseness • Dyspnea, stridor, cyanosis • Ddx: diphtheria, H. influenza epiglottitis *Older pax: common cold, bronchiolitis, bronchopneumonia*	**Diagnosis:** culture, antigen IF, lim sero **Tx:** no specific tx • Tracheostomy if severe • Support: hydration, ventilation • Treat secondary infection
Respiratory syncytial virus (RSV)	No hemagglutinin, neuraminidase.	Affects young children, peaks at 3 mths (may be rxn btw virus & maternal Ig)	**Bronchiolitis** (commonest cause in young child) • Fever, cough, wheezing (CXR: lungs patchy) • Obstruction of narrow bronchioles: dyspnea, tachypnea, cyanosis, inspiratory indrawing • Complications: secondary bacterial inf, otitis media, cardiac failure, apnoea. 5% mortality *In older children: URTI.*	**Diagnosis:** culture, antigen IF **Tx:** Ribavirin aerosol, Support, Isolate
Metapneumo-virus		Triggers wheezing in asthmatic children		
Adenovirus	DNA virus	40 serotypes	Infections of mucosa & lymphoid tissue • **URTI**: fever, pneumonia *[Ddx: flu, strep throat]* • **Conjunctivitis:** Acute follicular conjunctivitis, epidemic keratoconjunctivitis, pharyngoconjunctival fever • **Adenitis:** mesenteric adenitis, chronic tonsils/adenoid inf • **Others:** haemorrhagic cystitis, intussusception	**Diagnosis:** culture, antigen IF **Vacc:** Available against some serotypes, not used in SG
Rhinovirus *Picornavirus*	Small size, RNA genome Optimal growth 33degC	>100 serotypes, antigenic var Spread by contact & resp sec	**Common cold**, incubation 2-4 days. Complications rare but may ppt asthma, aggravate COPD	**Diagnosis:** culture for epidem only **Tx:** Symptomatic
Coronavirus		>3 antigenic types Zoonoses	**Common cold**: 15% of total **SARS**	**Diagnosis:** culture difficult **Tx:** Symptomatic, no vaccine

Enteroviruses – *Picornaviridae*

Recently reclassified to Enterovirus A-D, Enterovirus XX (over 60 serotypes)

Virus	Structure	Epi / Mech	Clinical Pre		Diagnosis / Treatment
Poliovirus	Enterovirus : • Small • No envelope • ssRNA R to 60 deg heat, disinfectants. Replicate in GIT Prefer warm moist env	• 3 serotypes • Fecal-oral transmission • Mostly eradicated but access issues in Africa / South Asia • Damage mainly imm mediated; delayed inf due to better hygiene results in worse dx.	90-95% subclinical infections, 4-8% minor flu-like illness However in 1-2% - **Polio:** Virus rep in GIT lymphoid tissue, then released and infects CNS gray matter, producing distinctive plaques • Aseptic meningitis • Ant horn cell inv: flaccid paralysis, denervation atrophy LL • Medulla inv: respiratory paralysis, death		**Vacc:** IM IPV (Salk) or PO OPV (Sabin) • Sabin can be given by untrained pax • Salk stops disease but not carriage (no IgA), Sabin prevents carriage (IgG & IgA) • However OPV may revert to wild type, can cause vaccine-associated paralysis • Eradication of polio changes risk-benefit calc, VAP now significant. ? Use Salk
EV71, CA16, CA24		Multiple genogroups, some are more virulent • 97-98 EV71 outbreak inTaiwan & Sarawak with high mortality Contagious, infects mainly 2-5y old	**HMFD** (Hand, Foot & Mouth disease) • Usually mild: fever, mouth ulcers, rash/blishers on palm, soles, knees, elbows, buttock • Extreme cases: polio-like paralysis, encephalitis, neurogenic pulmonary edema (EV71 affecting brainstem control of heart)		**Control:** Legally notifiable. Closure of preschools helps to stop spread **Vacc:** Clinical trial
Coxsackie virus A			Epithelial inf: Herpangina (mouth blisters), conjunctivitis	Encephalitis possible	**Dx:** No good lab test, PCR is best **Vacc:** None **Tx:** • Some use IVIG to treat severe inf, efficacy uncertain. • Pleconaril on clinical trial
Coxsackie virus B			Mainly muscular inf: myocarditis, Bornhom's dx (devil's grip). Referred intercostal pain minics appendicitis		
Echoviruses		30 serotypes	Wide range of diseases		
EV70			Acute haemorrhagic conjunctivitis		

Mosquito bourne viruses

VIRUS	STRUCTURE	EPI / MECH	CLINICAL PRE	DX/TX
Dengue *Flavivirus* *(Yellow fever is anr flavivirus)*	ssRNA virus Envelope glycoprotein determines serotypes	4 serotypes (1-4), some are more virulent. Infection results in immunity against the same serotype. Vector: Aedes aegypti / albopictus. Man is main reservoir Dengue replicates in monocytes & macrophages. • DHF: platelet activating factor rel, depleting platelets • Shock: release of vasoactive cytokines, complemenent activation (anaphylatoxin release) etc **Immune enhancement:** DSS occurs mainly in infants <1y & re-infected pax • These pt hv non-neutralizing Ig (for anr serotype but also cross-reactive) from prev inf or maternal Ab • Enhancing Ig forms imm cplx w virus • Imm cplx attach to macrophage Fc & internalized • Virus replicates in infected cell, activating mono/macro to release DHF/DSS mediators	**Dengue:** high fever, headache, retroorbital pain, rash, arthralgia (no inflammation). Only 15% of infected people are symptomatic **Dengue haemorrhagic fever** (DHF): • Continuous high fever (2-7 days) • + tourniquet test: inflating BP cuff induces petichiae • Petichiae, purpura, ecchymosis (non-blanching), epistaxis, gum bleed • Haematemesis, malena • Liver enlargement (due to liver Kupffer cells) • Thrombocytopaenia (<100k/mm^3 vs norm 400k) • Haemoconcentration: hematocrit inc 20% due to extravasation of plasma, also can see ascites, pleural effusion **Dengue shock syndrome** (DSS): short onset • Usu at time of or shortly after fall in temp (Day 3-7) • Warning signs: restlessness/lethargy, acute abdominal pain, oligouria, usual clinical signs of shock	**Dx:** • Early (viremic): PCR • Late: IgM • Both: NS1Ag • Hemaglutination inhibition **DHF/DSS:** • Vol replacement • Avoid salicylates (bleeding), use paracetamol. **Control:** • Vector control • Vaccine trial (fear: imm enhanemt?)
Chikugunya *Alphavirus*		Vector: Aedes aegypti / albopictus Endemic in India, outbreaks in Italy, Malaysia, SG	Differential diagnosis for dengue but usu not life threatening • Fever, rash, arthritis (w inflammation), photophobia	**Dx:** Serology, PCR
Jap Encephalitis *Flavivirus*	One serotype	Enzoonotic cycle involving vector (culex mosquito) & amplifying hosts (pigs/birds). Not endemic in SG Mainly affects children <15 yo. Virus enters CNS by • Capillary seeding through endothelium through BBB • Infection of nerve endings & axoplasmic tpt	Inapparent dx (majority) if viremia terminates bf virus enters brain **Encephalitis** otherwise with destructions of neurons & glial cells • Abrupt onset fever, headache, malaise • CNS signs: Drowsiness, vomiting, convulsions • Meningeal irritation : neck rigidity, + Kernig's sign • CSF abnormalities: ++ lymphocytes, ++ glucose, ++ protein • Sequelae common in survivors: motor, mental, behavior disorders	**Dx:** IgM **Vacc:** Inactivated vacc from inf mouse brain
Hantavirus *Bunyavirus*	RNA virus	Multiple hantaviruses Transmission • Each hantavirus infects a single rodent species • Transmission from inhalation of rodent excreta	**Haemorrhagic fever with renal syndrome** (HFRS) • 5 phases: febrile, hypotensive, oliguric, diuretic, convalescent • Haemorrhagic signs: petechiae, conjunctival, thrombocytopaenia, hemoconcentration, leukocytosis • Renal signs: hypotension, electrolyte imbalance in diuretic phase • Potentially fatal esp in oligouric phase. **Hantavirus pulmonary syndrome** (HPS) • Fever, myalgia, respiratory symptoms, acute resp distress	**Dx:** IgM, ELISA, PCR

Herpes viruses

Structure : dsDNA, with ether-sensitive outer membrane.
Replication : binding, replication using cellular machinery, packaging into capsid, host-derived viral envelope & budding.
Characteristic : All can remain latent & cause recurrent infection

Virus	Epi	Clinical Pre	Diagnosis	Treatment
HHV1 : HSV1 **Herpes Simplex Virus type 1**	Trans: Kissing. ~100% acquires inf by adulthood Primary inf usu subclinical Remains latent in sensory ganglia Travels down nerve fibres during reactivation	**Mainly above umbilicus: Vesicles** (due to lysed dead cells) • Acute herpetic gingivostomatitis • Herpes labialis (cold sore) • Herpetic whitlow on fingers (serous exudate vs purulent in staph) • Eczema herpeticum (Kaposi's varicelliform eruption) – superinf of eczematous skin • Keratoconjunctivitis (don't give steroids!) • Aseptic meningitis • Acute necrotizing encephalitis, temporal lobe necrosis + CNS signs. High mortality & morbidity • Disseminated herpes in immunocompromised	• Multinucleated giant cells not diagnostic; HSV also found in asymptomatic • HSV IgM in primary HSV inf • No rise in titre with reactivation	Neutralizing Ab do not prevent reactivation because latent virus is in immunoprivileged site. **Tx** • Acyclovir • Valaciclovir • Little value for recurrent dx **Neonatal herpes** C-section b/f rupture of mem
HHV2 : HSV2 **Herpes Simplex Virus type 2**	Trans: STD / shared towel Remains latent in lumbosacral ganglia.	**Mainly below umbilicus: Vesicles** (due to lysed dead cells) • Herpes progenitalis • Neonatal herpes due to infected mother: can be subclinical to severe; jaundice, hepatosplenomegaly, thrombocytopaenia.		
HHV3: VZV **Varicella-Zoster Vir**	Droplet transmission, highly infectious Remains latent in sensory nerve ganglion Recrudescent disease, in elderly or immunocomp. Source is own body. Zoster usu does not cause other zoster cases but can cause varicella outbreaks.	**Varicella (chickenpox)** • Incubation 2-3 weeks • Fever, vesicles (later pustules), trunk > extremities (centripetal dist) • More severe in adults than children • Complications: bact superinfection, aseptic meningitis, encephalomyelitis, hemorrhagic, pneumonia, arthritis. Overwhelming in immunosuppressed • Neonatal varicella can have high mortality. **Zoster (shingles)** • Vesicular eruptions appearing similar to varicella, but painful • Dermatomal distribution (usu thoracic "belt of roses") • If CN V_1 involved – iridocyclitis, keratitis, corneal ulceration • If CN VII (geniculate ganglion) inv: Ramsay-Hunt syndrome – vesicles in ext auditory canal, tympanic mem, ant tongue, CNVII palsy • Complications: encephalomyelitis, post-herpetic neuralgia	• Multinucleated giant cells • Virus isolation • IgM in both varicella & zoster	Inf with varicella does not give immunity to zoster. **Tx**: • Symptomatic tx, antihistamine and advice to keep clean to avoid secondary infection • Acyclovir **Control** • Live attenuated vaccine • VZIG in exposed high-risk • Barrier nursing

Virus	Epi	Clinical Pre	Diagnosis	Treatment
HHV 4: EBV **Epstein Barr Virus**	Ubiquitous in healthy adults "Kissing dx": shed in pharyngeal secretions, Transmitted by close contact	**Infectious mononucleosis (glandular fever)** • Incubation 4-7 wks • Most prevalent in seronegative children & young adults • Lethargy, anorexia, fever • Pharyngitis, exudative tonsilitis, lymphadenopathy, splenomegaly • Rash exacerbated by ampicillin. • Complications: hepatitis, aseptic meningitis, encephalitis, neuro, splenic rupture, myocarditis **Cancers** (Replicates in B cells, causing growth stimulation & immortalization) • Burkitt's lymphoma (B-cell), esp in areas with endemic malaria, AIDS pt. Causes deregulation of c-myc oncogene & ? suppress T-lym surveillance • Immunoblastic lymphoma (in pt with impaired T cell immunity) • Nasopharyngeal carcinoma	Atypical mononuclear cells: pleomorphic, primitive nuc, diffuse chromatin, some lobulated nucleus + Heterophile Ab (Paul-Bunnell test), haemagglutinate sheep RBC EBV IgM	**Tx** • Symptomatic • Avoid ampicllin
HHV 5: CMV **Cytomegalovirus**	Fetus can be inf in any trimester or perinatally Most inf asymptomatic antibodies in >50% pax except young children. Virus shed in saliva, tears, urine, secretions, milk & spread by close contact	**Congenital inf in infants** (inf in mother usu asymptomatic) • Congenital infection (milder) • Cytomegalic inclusion disease: jaundice, hepatosplenomegaly, microcephaly, mental retardation, etc • Postnatal hepatitis **Infectious mononucleosis syndrome** • Clinically sim to glandular fever but less pharyngitis & lymphadenopathy • Virus goes to peripheral blood leukocytes (PBL) or kidney, giving CMVuria Inf in immunocompromised following reactivation, can be severe and cause retinitis e.g. in AIDS. Also can cause Gullian-Barre syndrome	Throat swab or urine, then culture: Enlarged cells with intranuclear owl's eye inclusions Circulating atypical lymphocytes No heterophile antibodies Or IgM, IgG.	Imm clearance dependant on T-cell immunity. **Tx** • Ganciclovir **Control** • Isolation of newborns w CMV • CMVIg prophalyxis in CMV – organ recipients receiving CMV + organs
HHV 6	HHV6 + Ab+ present in healthy pax oral sec	• Rubelliform rash in child 0.5-3yr (exanthem subitum / roseolar infantum) • Confused with rubella • High fever, possibly leading to febrile fits • Leukopaenia with relative lymphocytosis • Spontaneous recovery		**Tx** • Antipyretic agents
HHV7		No association with human dx yet		
HHV8: KSHV Karposi Sarcoma assoc virus	Sexual transmission or through transplants	**Karposi's sarcoma** in AIDS pt • Malignancy of vascular endothelial cells • Purple lesions in skin, oral cavity, GIT, lungs		No antiviral or vaccine

MMR viruses

Virus	Structure	Epi / Mech	Clinical Pre	Dx/Tx
Measles virus *Paramyxovirus*	RNA	Ubiquitous inf of early childhood, acquired 5y without vaccination Spread by aerosol, v contagious Immunity from prior infection is lifelong	**Measles** (incubation period 10-14d) • Virus repi n resp epithelium: fever, conjunctivitis, rhinorrhoea, cough • Koplik's spots ('salt and pepper appearance') around parotid papilla heralds onset • Then maculopapular rash appears with some coalesced spots (due to virus replication in skin). No vesicles. Spreads from face to entire body. **Complications:** • Mucosal: conjunctivitis, otitis media • Respiratory: Bronchopneumonia, giant cell pneumonia • GIT: Diarrhoea • Post-infectious demyelinating encephalitis • Sub-acute sclerosing panencephalitis (SSPE), a slow virus infection (months-yrs) aft apparent recovery. Myoclonic seizures, intellectual deterioriation, fatal	**Dx** • Sample pharynx, conjunctiva, urine. Tissue culture to show multinucleated giant cells • IgM, IgG (retrospective) **Vacc** • MMR: live attentuated vaccine at 1 yr or earlier • MMR contraind: malnourishment, immunocompromise, pregnancy • Contacts with immunodeficiency: passive immunization with Ig
Mumps virus *Paramyxovirus*	RNA	Most inf age 5-15 Complications more freq in adults	**Mumps:** (Incubation 2-3 weeks) • Salivary gland enlargement, pain aggravated by eating (esp parotid) • May hv cervical lymphadenopathy **Complications:** • Aseptic meningitis common but mild • Orchitis, can lead to subfertility if bilateral (infertility: ask abt prior mumps) • Pancreatitis. Can affect other organs rarely.	**Dx** • Sample saliva, throat, urine, CSF in meningitis. Tissue culture to show multinucleated syncytial cells • Can haemagglutinate • IgM, IgG **Vacc:** MMR
Rubella *Togavirus (non-arthropod bourne)*	RNA 1 serotype	Respiratory transmission, moderately infectious. Recurrent spring epidemics Often subclinical / mild but variable	**German measles** (incubation 2-3 weeks) • Prodrome of headache, fever, conjunctivitis, URTI sym • Forscheimer's spot: rose spots on palate herald onset of skin rash • Typically measles like rash, may be a bit more discrete & smaller but hard to ddx • Tender lymphadenopathy **Complications:** Arthralgia, arthritis, Encephalitis, Purpura, thrombocytopaenia & haemorrhage **Congenital rubella sym:** Teratogenic to fetus esp in 1st trimester; higher if earlier • Stillbirth, spontaneous abortion • Ocular lesions: cataract, retinopathy, micropthalmia • Sensineural deafness • CNS: microcephaly, retardation, spasticity • Many other malformations including heart	**Dx** • IgM • ToRCHeS IgG panel • Virus isolation time consuming **Mgt** • Quarantine pt • Passive immunization early after exposure • Screen all pregnant mothers antenatally for rubella Ag **Vacc:** MMR. Avoid pregnancy 3 months following vaccination

Miscellaneous viruses

Virus	Structure	Epi / Mech	Clinical Pre	Dx/Tx
Parvovirus B19	ssDNA: smallest DNA vir Replicate in rapidly dividing cells Parvovirus B19 infects only humans	Transm: body fluids, blood, mother to fetus Most inf asymptomatic	**Fifth Disease: Erythema Infectiosum** (incubation 4d-2w) • 1st phase: viremic, present in URT. Wk 1 - Fever, malaise, myalgia, chills itching • 2nd phase: Immune complex mediated. Rash / slapped cheek appearance • Targets erythroid progenitor cells: causes lysis & anemia. Can also affect lymphocytes, granulocytes, platelets **Complications:** Anemia. Targets erythroid progenitor cells leading to lysis; can also affect lymphocytes, granulocytes, and platelets. At risk groups - • Can cause transient apalastic crisis in pt with chronic haemolytic anemia (thalassaemia, sickle cell) • Can cause severe aplastic anemia in immunocompromised pt • Maternal infection (esp first trimester) can cause severe fetal anemia (non-immune hydrops fetalis)	**Dx** • Virus hard to grow • IgM, IgG rising titres • PCR **Tx**: No specific treatment, vaccination. Avoid exposure
Poxviruses	Large virus, dsDNA	Many sp, inf var hosts	Usu with a rash	
Variola		Inf human only Respiratory transm Now eradicated	**Smallpox** (12 day incubation) • Virus in internal organs, 50% mortality • Rash: papular, vesicular, pustular	**Vacc:** cowpox vacc against smallpox. But with complications inc fatal encephalitis.
Vaccinia			**Coxpox**	
Molluscum contagiosum		Worldwide dist, more common in children Transm: contact, fomites, swimming pools, STD	**Molluscum contagiosum** (incubation 1w – 6m) • Papule growing into waxy, dome shaped nodule (usu umbilicated ctr) • 1-20 lesions usual, occasionally 100s. usu painless. • On trunk, proximal extremities (also pubic area in adults) • Lesions persist for 2 months, dx lasts 6 mths.	**Dx:** Clinical appearance, confirm by EM. Infection is usually benign and painless **Tx:** spontaneous recovery
Rabies *Rhabdoviridae*	ssRNA enveloped, bullet shape	Zoonosis: dog bite, inhaled in bat-infested cave Infectivity higher if bite on face, lower if LL	**Rabies** • Enter peripheral nerve through NMJ, spread to CNS in Schwann cell endoneurium • Prodromal phase: pain at bite site, GIT/URT sym, irritability, hydrophobia • Excitation phase: hyperventilation, disorientation, seizures • Paralytic phase: almost invariably fatal due to cardiac & resp inv	**Dx:** Histo: Negri bodies or antigen detection. Serology is too slow **Tx:** • Wound treatment • Passive immuniz: rabies Ig at wound + IV. • + Actv immuniz (inactivated whole virus): incubation period can be long • Control: dog vaccination, stray dog ctrl

Slow virus diseases

Progressive pathological processes mainly involving CNS

VIRUS	STRUCTURE	EPI / MECH	CLINICAL PRE	DX/TX
Measles			Subacute sclerosing panencephalitis (SSPE)	
Rubella			SSPE in congenital infection	
JC (Human polyomavirus)	dsDNA	Reactivation of latent inf. Primary inf probably childhood, PML not contagious In immunocompromised pt, 10% of HIV pt	**Progressive multifocal leucoencephalopathy (PML)** • Infection of oligodendrocyte • Mental status changes: deficits in speech, lang, visual, weakness • CNS signs: CN palsy, sensory/vision loss, coordination loss	**Dx:** Brain biopsy, CT/MRI, PCR of CSF
Prions (not viruses)	Misfolded prot. R to chem agent Not immunogenic	Mode of transm usu unknown, familiar clustering & iatrogenic inf documented Usu affects old Immunosuppression has no effect	**Subacute spongiform encephalitis / Cretzfield Jacob Dx** Long incubation period, then dementia, ataxia, yoclonic jerks. Death in 1yr • Abnormal prions combine with normal prot to induce rep of abnorm • Spongiform appearance of CNS, vacuolated neurons, fibrous gliosis • No inflammatory rx (non-immunogenic)	
		Usu affects young	**New variant CJD:** prolonged dx, behavioural changes. ? Link to CJD	

Gastroenteritis viruses

VIRUS	STRUCTURE	EPI / MECH	CLINICAL PRE	DX/TX
Rotavirus *Reovirus family*	No envelope Double-shell capsid Wheel appearance	Groups A-E, several serotypes. Affects young children (usu 6mth-2yr) Majority of children have Ab by age 6 Fecal-oral transmission, high vir load in stools	**Gastroenteritis in young child** (incubation: days) • Virus infects epithelial enterocytes of small intestinal villi • GIT sym: diarrhoea, vomiting, abdo pain, fever • Dehydration due to fluid loss **DDx:** bacterial (E. coli, non-typhi Salmonella), Parasitic (giardia)	**Dx**: EM, ELISA, Latex agglutination, PCR **Tx:** • Breast milk IgA protective, avoid bottled milk • Correct dehydration & electrolyte imbalance (rehydration salt, drip) • Sanitation & prevent nosocomial transmission **Vacc:** Oral live attentuated, by 6 mth. RotaTeq (pentavalent) or Rotarix (monovalent)
Norwalk virus *Norovirus genus* *Calicivirus family*		Affects adults Highly infectious. Causes outbreaks / epidemics e.g. in restaurants, assoc w water, food, shellfish	**Gastroenteritis in adult** (incubation: rapid) • GIT sym: diarrhoea, vomiting, abdo pain, fever • Mild, self limiting, lasts 1-2 days	**Dx**: EM, ELISA, PCR **Tx:** Supportive.

Hepatitis viruses

Virology			Source
HAV	RNA	picornavirus	- Shellfish: cockles & oysters
HBV	DNA	hepadnavirus	- Blood/needle, maternal-infant, sexual (inf man only)
HCV	RNA	flavivirus	- Blood (infects man/chimps)
HDV	RNA	satellite (plant)	- Blood, only in coinfection or superinfection with HBV
HEV	RNA	calciviridae	- Water: fecal-oral transmission

There are other non Hep A-E viruses!

The hepadnaviruses are species specific; HBV is the only one to infect humans. It has a double-stranded DNA of unequal length and starts replication by completing the shorter DNA strand with reverse transcriptase. HBV DNA codes for overlapping envelop, core, polymerase, and X genes (X is a suspect oncogene).

HBV has 8 genotypes and HCV has 6, some of which are more responsive to therapy. HAV only has 1 serotype. New knowledge – HCV with the right IL28B gene is more responsive to therapy!

HDV is a defective virus and needs a HBsAg coat to infect. Hence HDV infection occurs only at the same time as HBV (coinfection) or in HBsAg carriers (superinfection).

Epidemeology

Acute hepatitis	: 50% due to HBV, 20-30% due to HAV except in epidemic years
Chronic hepatitis	: 70% due to HBV, 20% due to HCV in singapore. Reverse in Japan.
	: Alcohol accounts for 10-15%
HCC	: 85% HBV related, 15% alcohol related, 8% HCV related.

Hep B

HBV endemicity of a country is directly related to carrier prevalence. With mass vaccination infection rates have decreased markedly, especially the rate of neonatal infections. However seroprevalence is still 8% in >60y and 6% in >40y. Risk is greater in Male > Female, Chinese > Malays > Indians, and as usual, higher in the immunocompromised, and in those with exposure to HBV blood (e.g. IVDU, sexual partners etc). Prevention of Hep B infection involves standard blood-bourne precautions, PPE, autoclave & vaccination.

HAV

Outbreaks occur; travellers, sweage workers, food handlers and other HxV viruses are especially at risk. Prevention is simple – vaccination, avoidance of contaminated food, boiling, or chlorine (e.g. swimming pools). In Singapore – hygiene in the past was poorer, prior HAV exposure and hence immunity used to be 100%; however, youths today have no antibodies and are susceptible.

HAV and HEV appears in faeces before symptoms appear and this contributes to the spread of infection.

Clinical presentation

Clinically, all the hepatitis viruses present as hepatitis, after an incubation period of

HAV - 4-6 weeks
HBV - 3-4 months
HCV - 6-12 weeks

Symptoms & signs

- Nonspecific immune response symptoms (TNF & interferon release): fever, malaise etc
- Hepatitis symptoms: Jaundice, elevated AST & ALT
- Acute hepatitis can lead to liver necrosis and failure.

Variations

- Acute HBV tends to be more severe than HAV or HCV.
- HEV typically causes prolonged jaundice (months)
- HEV tends to be symptomatic in older people, and causes severe disease in pregnant women with 25% fatality.

Differentials

Hepatitis can also be due to non-infectious causes, e.g. drug-induced or autoimmune. Non-hepatitis virus infectious causes include TB, other viruses that sometimes cause mild hepatitis (dengue, EBV), and viruses that rarely cause severe hepatitis (CMV, HSV) especially in the immunocompromised

Sequelae of acute infection

HBV and HCV can progress to chronic hepatitis, HCV characteristically with fluctuating liver enzymes. (chronic HEV has also been described). Chronic hepatitis causes liver fibrosis, cirrhosis, and eventually cancer (interacts with alfatoxin RR 60). Portal hypertension also results in esophageal varices. Polyarteritis nodosa and glomerulonephritis are possible.

Hep B in ADULTS:

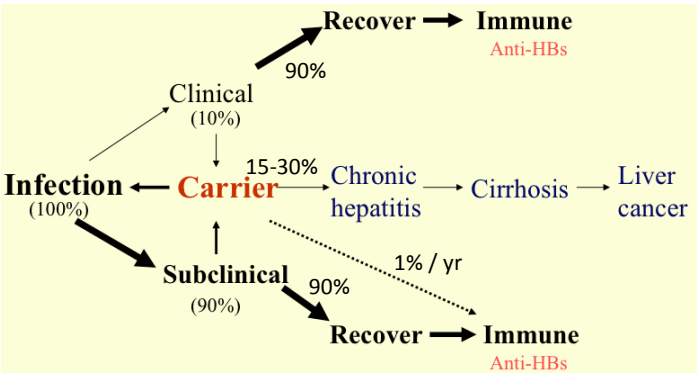

HCV in ADULTS: 60-80% of infected patients become carriers.

Maternal to infant transmission

HBV : HBeAg + mothers: 90% carriers, of which 30% develop complications
: HBeAg – mothers: 10% carriers.
: Maternal-infant transmission is high in Asia, so 75% of infected develop chronic dx

HCV : Mother-to-child transmission rare due to low circulating virus load (except HIV + mother)

Serology patterns

HBV:	Core	HBcAg	- Not detectable, always coated with HbsAg (Dane particle)
	Core-assoc	HBeAg	- Marker for viremia & infectivity
	Surface	HBsAg	- Marker for HBV. Can exist alone or as Dane particle.
			- Has dominant 'a' epitope against which anti-HBs forms

Antibodies:	anti-HBc IgM	- Indicates acute infection.	Not protective.
	anti-HBc IgG	- Indicates chronic/past infection.	Not protective.
	anti-HBs	- Indicates past inf or vaccination	Protective
	anti-HCV	- Indicates hx of exposure (past or current chronic inf)	

Patterns:	HBsAg	IgM anti-HBc	IgG anti-HBc	Anti-HBs
Acute infection	+/-	+	-	-
Chronic carriage*	+	-	+	- (hence sick)
Past infection	-	-	+	+
Vaccination	-	-	-	+

Notes

- Carrier is defined as HbsAg detectable in blood 6 months apart.
- HBV DNA: + initially, but can become – when the virus load decreases, even as HbsAg is still present. HBV DNA – does not mean patient is cured, HBV resides not in blood but in the liver.

Order of events

- Acute HBV: HBsAg detectable --> IgM anti-Hbc --> IgG anti HbC --> anti-Hbs late.
- Patients infected with HBV from birth undergo an immunotolerant phase while young, then an immunoclearance phase in which the body tries to clear the virus. It is during the immunoclearance phase that the manifestations of hepatitis appear.
- During the immunoclearance phase, patients chronically infected with HBV may undergo seroconversion from HBeAg+ / anti-HBe –, to HBe Ag - / anti-HBe +. This indicates a fall in viral load and infectivity.

HBV mutants

- Pre-core mutants (do not make HBeAG): HBeAg - viremia
- S mutants (mutation at 'a' epitope): HBsAg – viremia. Vaccine escape mutants against which the vaccine is not effective. Frequency is low in Singapore.

Serology: Diagnosis

HBV : HBsAg or IgM anti-HBc
HCV : HCV-RNA (confirm: RIBA. Alt: peptide strips) - IgM anti-HCV low sensitivity

HAV : IgM anti-HAV
HEV : IgM anti-HEV & IgG anti-HEV (occasionally IgM spike fades quickly)

Vaccination

HAV & HBV vaccines are available; HBV vaccine also automatically protects against HDV. HEV vaccines are on trial but the antibodies do not last.

Hep B:

- Pre-infection: vaccination gives 99.5%-100% protection
- Post-infection: vaccinate + HBIg
- Infants from HBsAg + / HBeAg – mother : vaccination gives 100% protection
- Infants from HBsAg + / HBeAg + mother : vaccination alone 80% protection
  : vaccination + HBIg 90% protection

1st gen HBV vaccines : plasma based, containing HBsAg purified from donors.
2nd gen HBV vaccines : yeast based recombinant 'a' epitope
: some non-responders who may or may not be protected
3rd gen HBV vaccines : mammalian cell based, with pre-S1, pre-S2, HBsAg peptides.
: more effective, may work in vaccine escape mutant & non-responders

Management

HBV & HCV carriers suffer worse outcomes should they be infected with HAV. Advise carriers to avoid liver damage by avoiding alcohol and taking available vaccinations.

Where the exact hepatitis virus is uncertain, advise against sexual intercourse to avoid infecting partners in case of HBV/HCV.

Cooking for family is OK with good hygiene to prevent fecal-oral transmission

HIV

Virology

HIV is a compact ssRNA virus, with a capsid (p24), inner & outer envelopes. gp41 & gp120 inner & outer envelope glycoproteins bind specifically to CD4 receptors on T helper cells and macrophages, enabling HIV entry into these cells. CXCR4 & CCR5 chemokine receptors are also implicated in HIV attachment. Once inside the cell, viral reverse transcriptase makes DNA from RNA; viral DNA is then integrated into host DNA by viral integrase. Synthesis of viral RNA & proteins is carried out by host machinery, and following virus budding, p24 self assembles to form the viral capsid.

There are two major types: HIV-1 (more common) and HIV-2 (africa). There are several subtypes and too many strains to count. There can even be multiple strains within 1 individual! This is because HIV has an error-prone reverse transcriptase and mutates quickly (especially gp120 & gp41 which are subject to selection); it also makes vaccines against HIV hard to create.

Stage	Clinical presentation	Serology
1) Acute seroconversion illness	Flu-like symptoms Meningoencephalitis possible	Spike in p24 antigen which falls IgM develops and falls IgG persists
2) Latent asymptomatic period	**Autoimmune manifestations:** - reiter's syndrome - bell's palsy - guillain-barre syndrome - demyelination neuropathy - idiopathic thrombocytopaenia	p24 levels low IgG high T helper cells gradually depleted
3) Symptomatic (Pre-AIDS)	**Opportunistic infection:** - TB - Herpes - Molluscum contagiosum - Pneumocystis carinii pneu - Cryptococcus - CMV - Pneumocystis	CD4 count falls Early AIDS CD4 >500
4) Full blown AIDS	**AIDS defining illnesses** - Kaposi's sarcoma (HHV8) - Lymphoma	CD4 > 200 No T cell stim – Ab levels fall HIV replicates – p24 rises

Epidemeology

Risk of infection per exposure:

Mother to child	25%	Receptive anal sex	0.1 – 0.3%
Needle sharing	0.6%	Receptive vaginal sex	0.08 – 0.2%
Needlestick injury	0.3%	Insertive vaginal sex	0.03 – 0.09%

Diagnosis

Take a good history! Some patients may present with just a fever and skin rash. Look at suggestions of opportunistic infection (especially in the mouth). In patients with 1 STD, suspect another. In IVDU, suspect HIV, HBV, HCV

Incubation period: From time of infection to time of symptom presentation
Window period: From time of infection to time at which HIV is detectable

Using antibody tests, window period > incubation period (need to wait for body's response)
Using antigen tests, incubation period > window period

Lab will routinely screen for both antibodies and antigens to shorten the window period. However do not reassure a patient too early that he/she is HIV-free, as he may be within the window period.

Methods for lab diagnosis

1) ELISA is a good sensitive first line screening (usually combined HIV1/HIV2 assays are used). However during the window period (can last up to 6 months), anti-HIV antibodies may not be detectable. Do not declare a patient to be AIDS-free too soon!

2) PCR is useful to detect AIDS during the window period, or to screen infants born to HIV + mothers for whom the ELISA test will not be useful as they have anti-HIV maternal antibodies.

3) Confirmation of positive results by a second test is mandatory and western blot is the usually used.

4) Saliva sample-based rapid antibody test which can be done in the privacy of the patient's home.

Treatment

Effective treatments are available but these do not cure. Effective viral suppression to very low levels can allow patients to lead a normal life, and help to prevent spread of HIV. (the “seek-treat-retain” strategy). It is important to treat other STDs as syphillis ulcers etc will increase the chance of spreading AIDS.

Ask newly diagnosed patients if they are married, and if they know how to protect their partners. Test partners & counsel on prevention of infection. Truvada, a drug already used to treat HIV, can protect uninfectd high-risk individuals from contracting AIDS if taken daily before and after exposure. However this indication is controversial as it might encourage poor condom use, and breed antiretroviral resistance if improperly used.

There are many other social and legal issues, including affordability and stigma. In the US, 20% of HIV patients are undiagnosed, and 50% of the known infected not involved in care. CD4 counts are often low at presentation and initiation of treatment. In Singapore, HIV + individuals are obliged by law to inform their partners before any sexual activity.

Malaria.

M2 Microbiology
Nigel Fong

Malaria

Malaria has a huge and increasing disease burden. It is endemic in South and Southeast Asia, Africa, Central & South America. Singapore is nominally malaria free, but imported cases and local outbreaks have occurred. South-east Asia is a hot spot for multi-R malaria!

Causative agent: Malaria is caused by Plasmodium spp, which belongs to the Apicomplexa family of intracellular parasites (also inc. Toxoplasma & Cryptosporidium). The apicomplexa are named after their apical complex, which is specialized to invade cells.

Subspecies	% of singapore cases
P. falciparum	25.8 %
P. vivax	70 %
P. malariae	-
P. ovale	-
P. knowlesi	1.1 %

P. knowlesi is a zoonosis from monkeys. It is common in Sabah & Sarawak, but also exists in the deep jungles of western Singapore (western catachment / SAF training areas).

Transmission **:** by *Anopheles* mosquitoes (bite from dusk to dawn, rarely in urban areas)
A. sundaicus – coastal/brackish water
A. maculatus – clear water, hilly areas.
: Rarely, transmission due to transfusion, mother to child, or lab acquired

Plasmodium life cycle

- Mosquito bite - injects sporozites

- LIVER : Sporozites infect & multiply in liver cells (incubation 10-14d)
  : Vivax & ovale may remain latent as hypnozoite (asymptomatic)

- BLOOD : Merozoite infects RBC & feeds on hemoglobin
  - Initially, as immature trophozoite (ring form) then to schizont
  - Hemolysis releases plasmodium to infect more RBC
  - Gametocytes (sexual form) may be produced

- Mosquito bite – ingest gametocytes. Sexual cycle occurs in the mosquito.

Pathogenesis

Incubation: There is a 10-14 day asymptomatic incubation period, while the plasmodium multiplies in liver cells. Exception – if malaria is transmitted through blood-bourne routes (transfusion, needles, transplacental), infectious forms of plasmodium may be inoculated. In such a case, malaria can develop within hours; there is no 10-14d window.

Symptoms: Clinical symptoms develop during the erythrocytic cycle. Clasically, fever spikes and subsides in a cyclic manner: each wave of maturing plasmodium precipitates a wave of RBC hemolysis, which causes TNF/IL-1 release and hence a fever spike. Anemia can result due to RBC damage. Symptoms are often varied and non specific.

Organ damage: Infected RBC tend to adhere to capillaries (increase chance of ingestion by biting mosquito, cf arteries/veins). This is especially so with P. falciparium – the resulting capillary occlusion and fall in perfusion can result in organ damage.

Latency: *P. vivax* & *P. ovale* can remain latent as hypnozoite and only present later! If hypnozoites are not eradicated, relapsing malaria may present.

Clinical algorithm

1. Is malaria possible? **DO NOT MISS MALARIA**
   - Malaria can mimic many diseases.
   - Take a good travel history; suspect in patients with fever + travel hx / foreign patient

2. Is falciparum malaria likely?
   - Falciparium malaria is life threatening and can cause death within a day. Even with previous exposure, immunity is only partial.
   - Severe infection due to P. vivax and P. knowlesi occasionally reported

3. Are there signs of end-organ damage (esp P. falciparium)
   - CNS: confusion, coma
   - Acute respiratory distress syndrome
   - Blackwater fever: RBC hemolysis resulting in black urine & kidney failure
   - Abnormal vital signs

4. Parasitological diagnosis: species & quantification
   - Note: there is a chance of co-infection with multiple plasmodium species

5. Are IV antimalarials required?
   - Indications: extremely ill patient / unable to take PO medications e.g. vomiting

6. Specific therapy
   - Consider resistance profile from geographic area.
   - Can chloroquine be used?
   - Different treatment necessary to eradicate latent hypnozoite.

Lab diagnosis

Giemsa-stained light microscopy of peripheral blood films is the oldest and best method. Both a thick and thin smear is done:

Thick film - Sensitive, used to detect presence of parasite.
Thin film - Allows identification of malaria species

Thick films: RBCs lysed. Trophozoites appear as streaks of blue cytoplasm

Thin films: *P. falciparum*
- Ring form : Multiple inf single RBC, inf RBC same size.
- Gametocytes : Crescentic (sausage) shape
- Schizont : Rarely seen, indicates severe dx

P. vivax - Infected RBC enlarged, with Schuffner's dots (indentations)

P. ovale - Similar to P. vivax, oval RBCs

P. malariae - Band-like growing form

For P. falciparum, only ring forms & gametocytes usually seen.
For the others, all forms can be seen

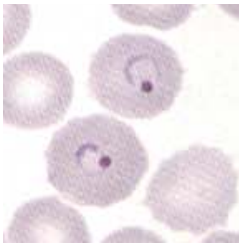

P. vivax

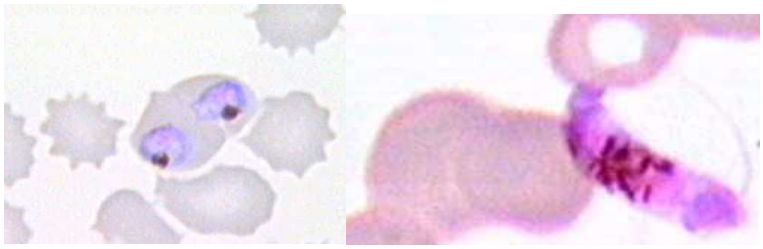

--------*P. falciparum* -------

Antigen diagnosis (e.g. ICT Malaria Pf & NOW Malaria) is a newer (but more expensive) diagnostic method. Differentiation of falciparium vs non-falciparium is possible using a falciparium-specific antigen

pLDH	Parasite lactate dehydrogenase	- In all malaria sp, indicates viable parasites
HRP-2	Histidine-rich protein 2	- P. falciparium specific. - Disadv: may persist aft parasite clearance not prod by gametocytes

Treatment

P. vivax, P. ovale, P. malariae

PO Chloroquine
+ PO Primaquine - clear hypnozoite (Check G6PD: may hv hemolysis in G6PD pt)

Chloroquine resistance emerging esp. in indonesia.
May be wise to not take the risk in patients with severe disease.

P. falciparum

PO/IV Artesunate (an artemisinin)
+ PO Doxycycline / IV clindamycin (2 drugs to prevent resistance)

Due to resistance, chloroquine is seldom useful against P. falciparum.
Artemisinin resistance is also emerging in cambodia.

P. knowlesi

PO Chloroquine (primaquine is optional)

Prophylaxis:

PO Mefloquine (psy disturbances, ?safety in 1st trimester)
PO Doxycycline (avoid in young children)
PO Atovaquone/proguanil (expensive)

Also – minimize bites: DEET-containing repellents, mosquito nets, long sleeves..
Consider standby antimalarials to take if fever, if med attention is inaccessible.